

# **ECG Interpretation: Advanced--Stump the Chump??**

William M. Miles, MD, FACC, FHRS

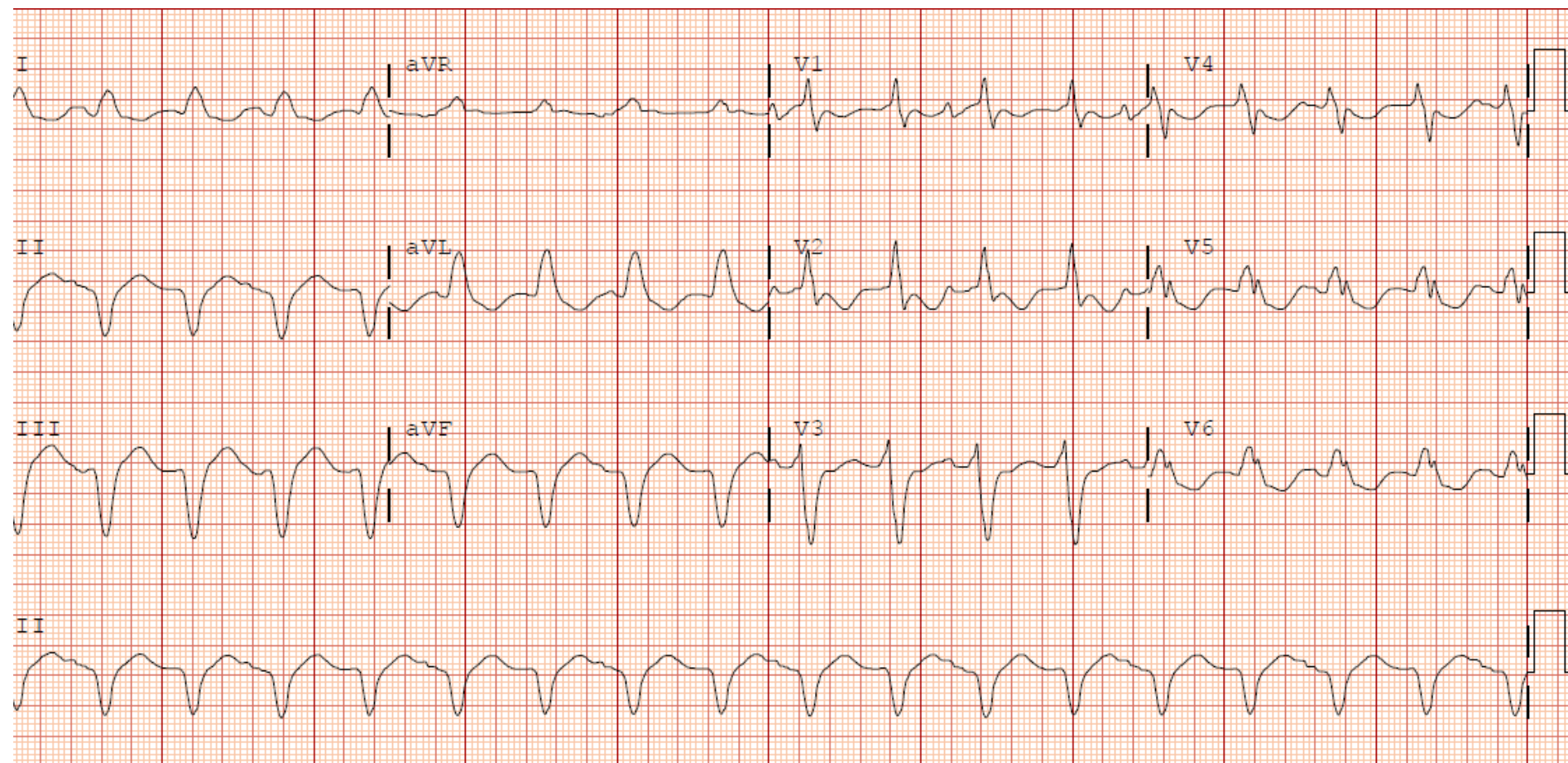
Professor of Medicine

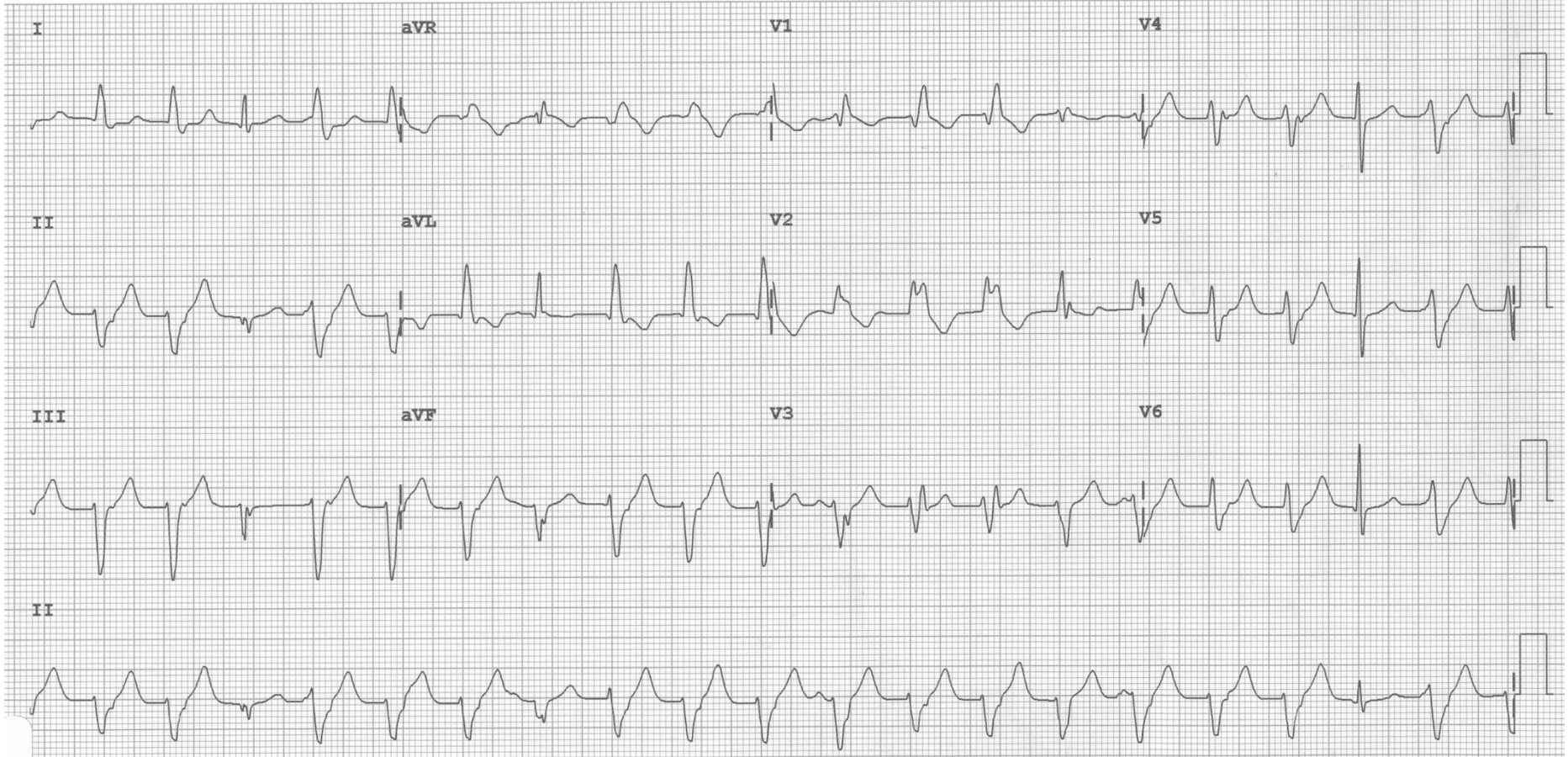
Silverstein Chair for Cardiovascular Education

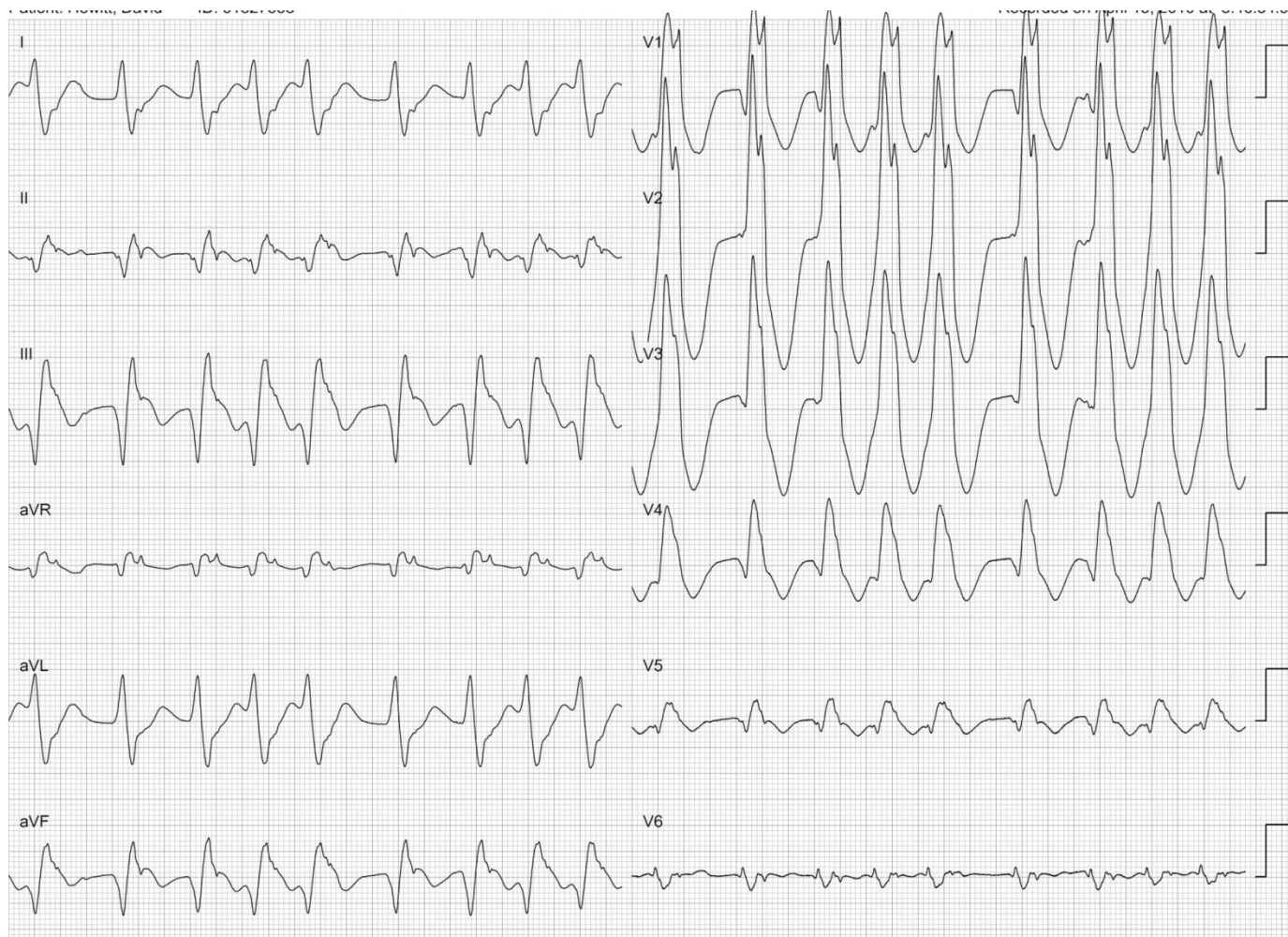University of Florida College of Medicine



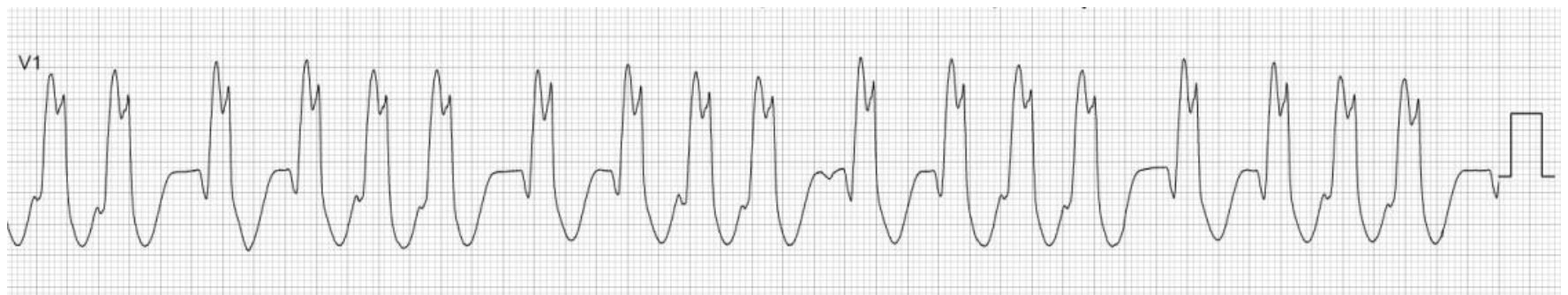AMERICAN  
COLLEGE of  
CARDIOLOGY




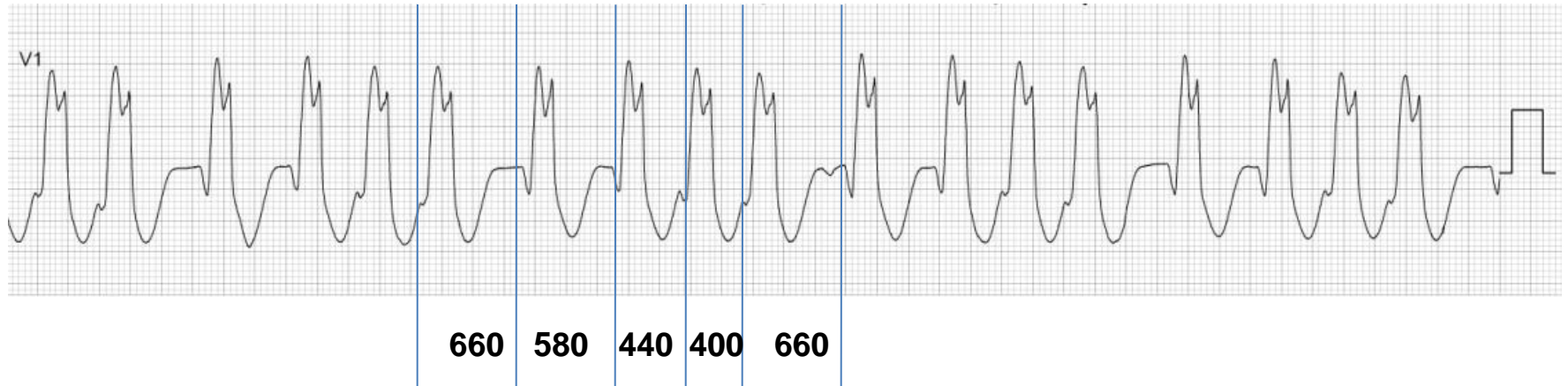




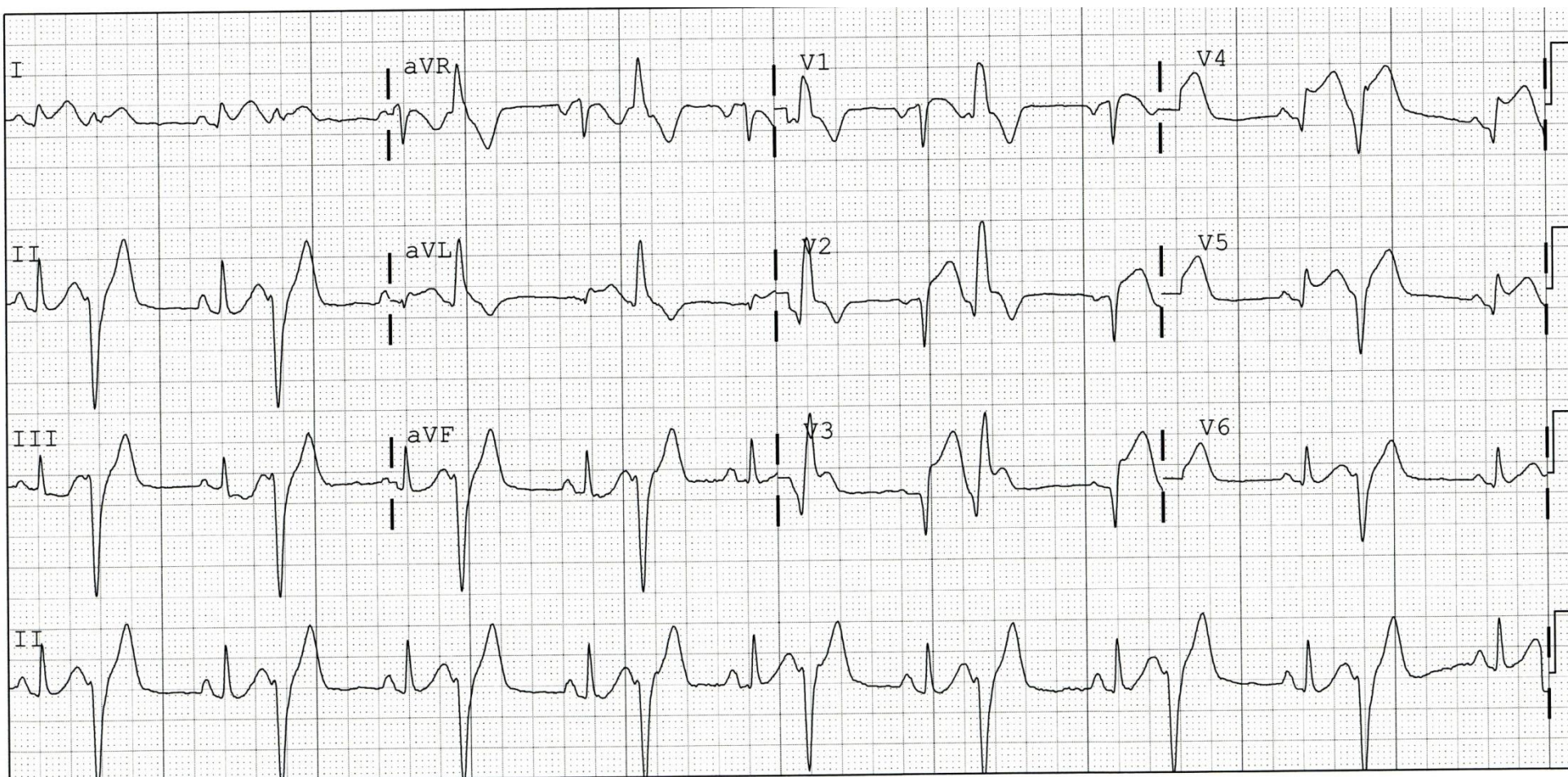
68 y.o. male with  
ischemic  
cardiomyopathy,  
presents with  
SOB and  
dizziness



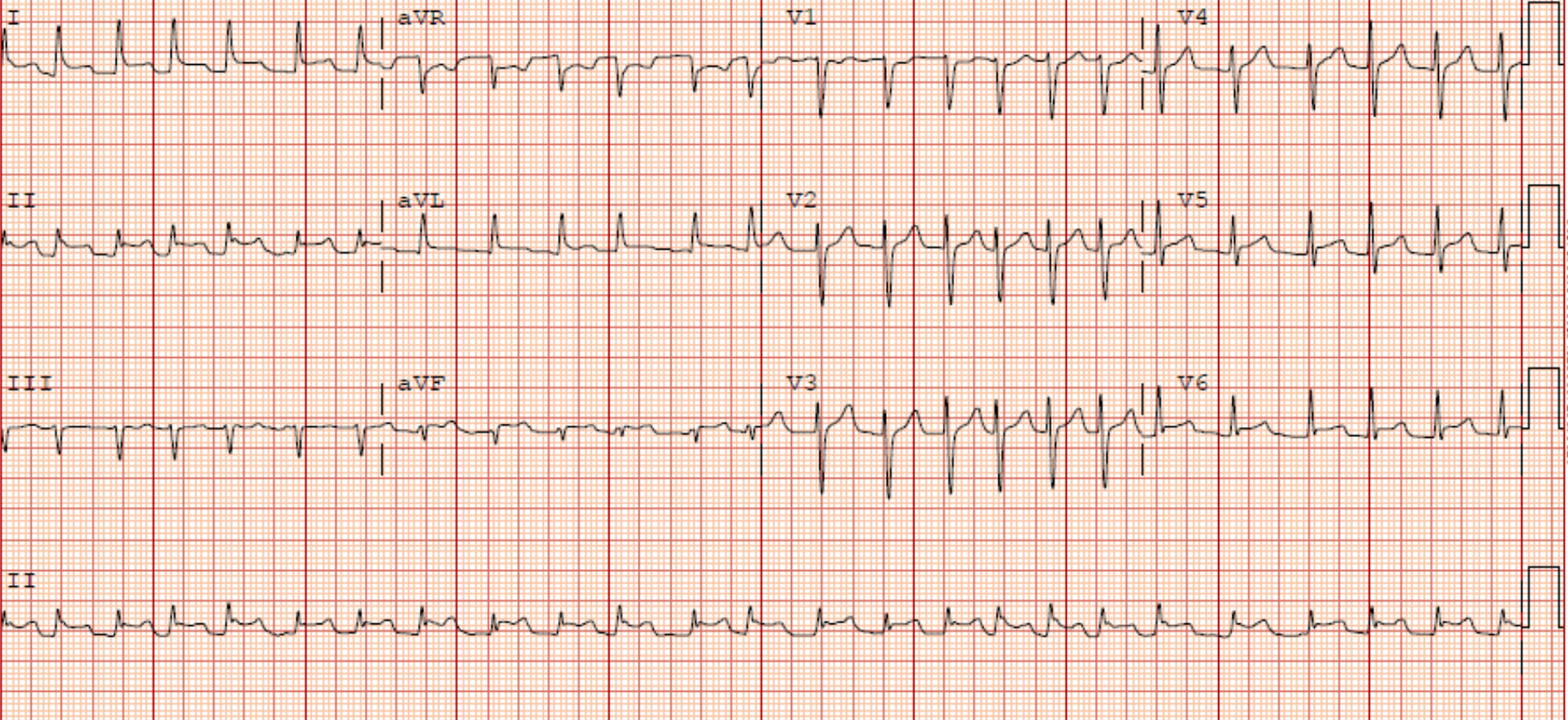


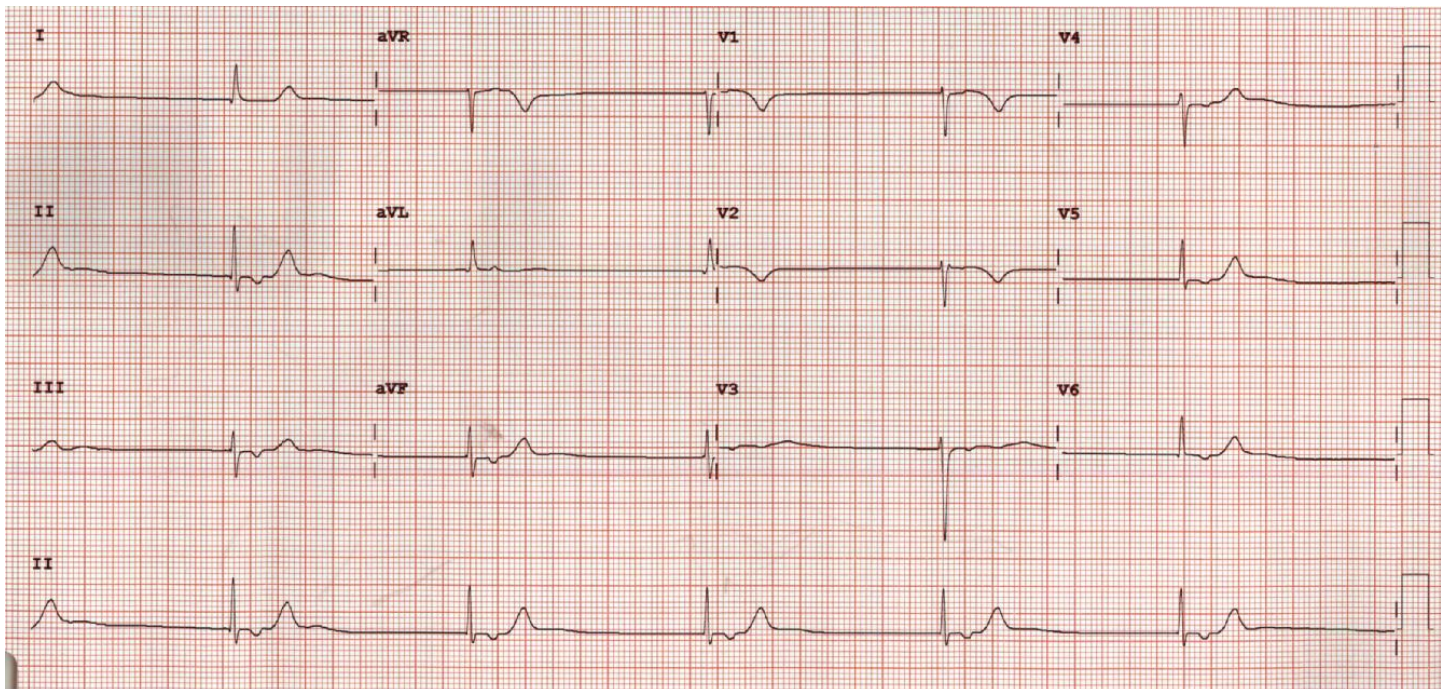
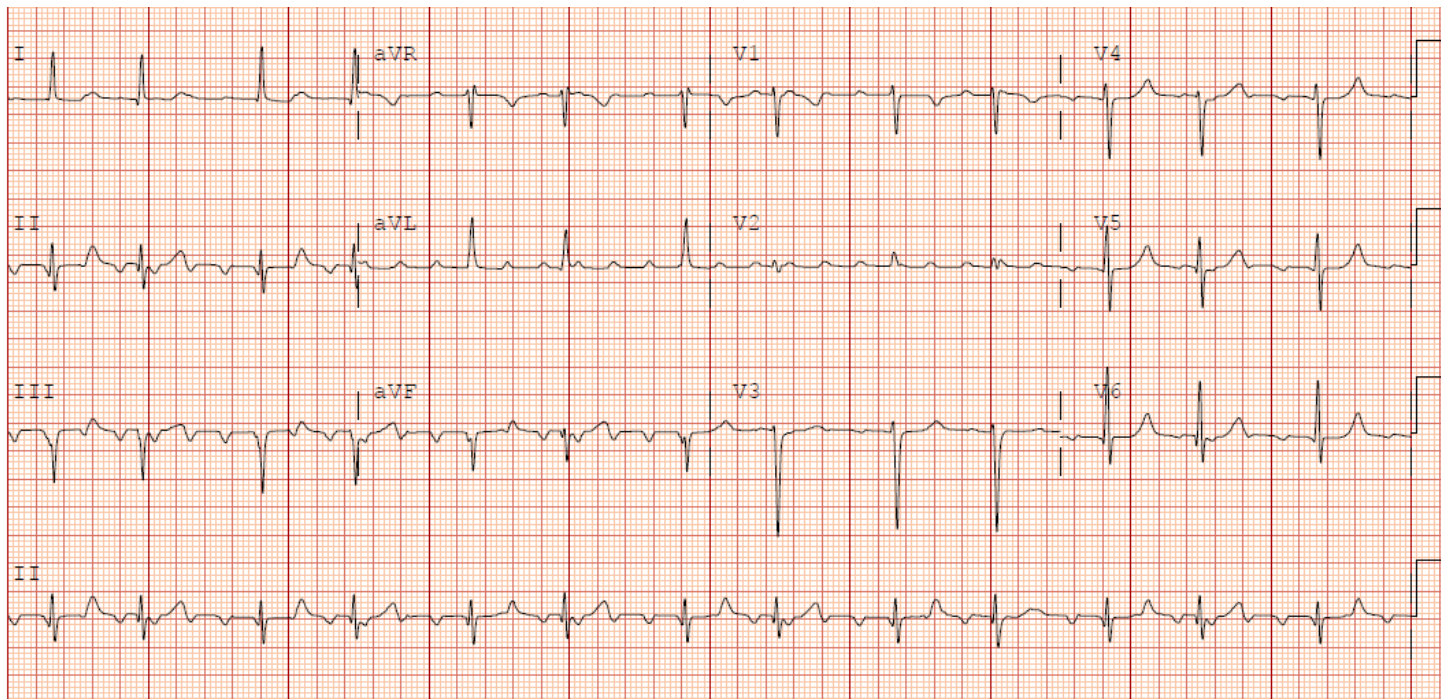


**Karel Frederik Wenckebach**



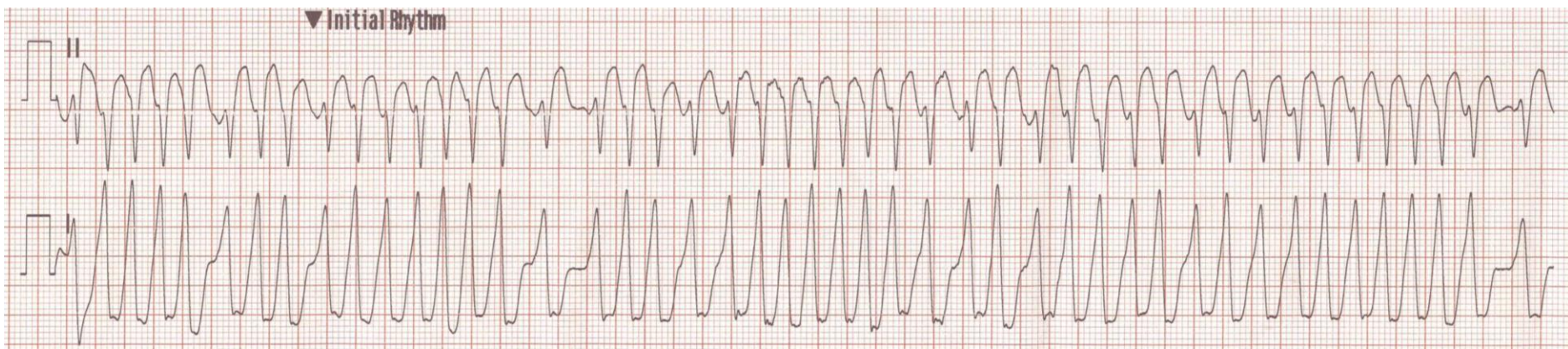








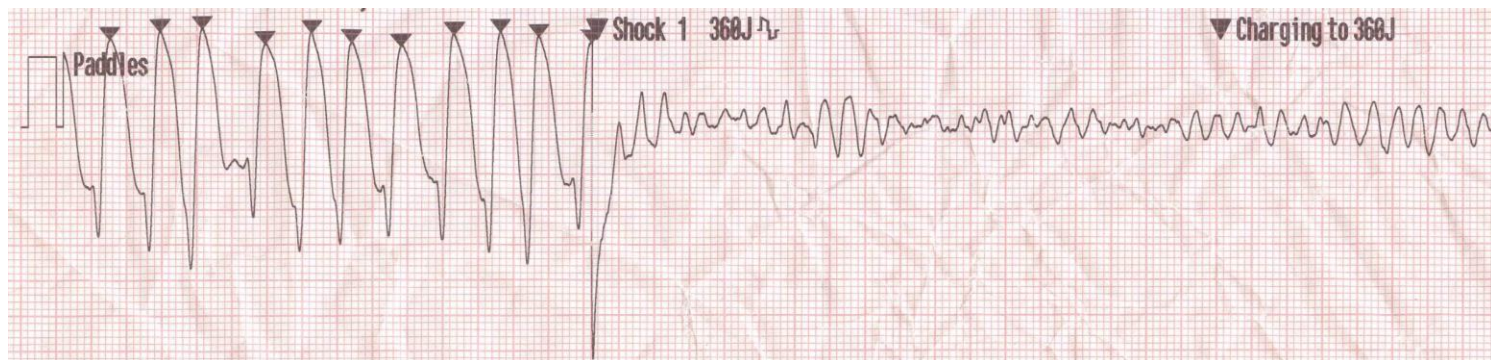
▼ Initial Rhythm



Paddles

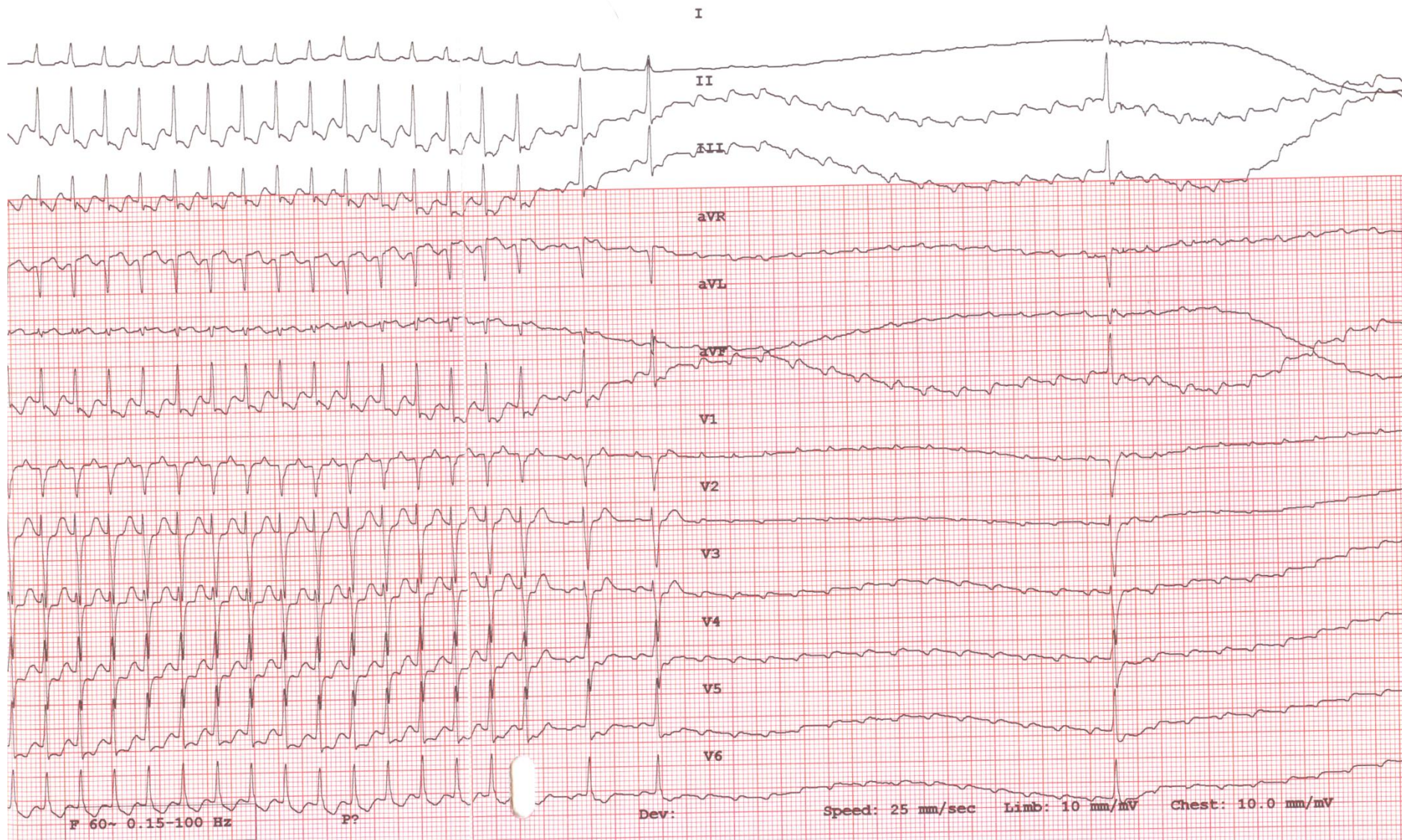
▼ Shock 1 360J

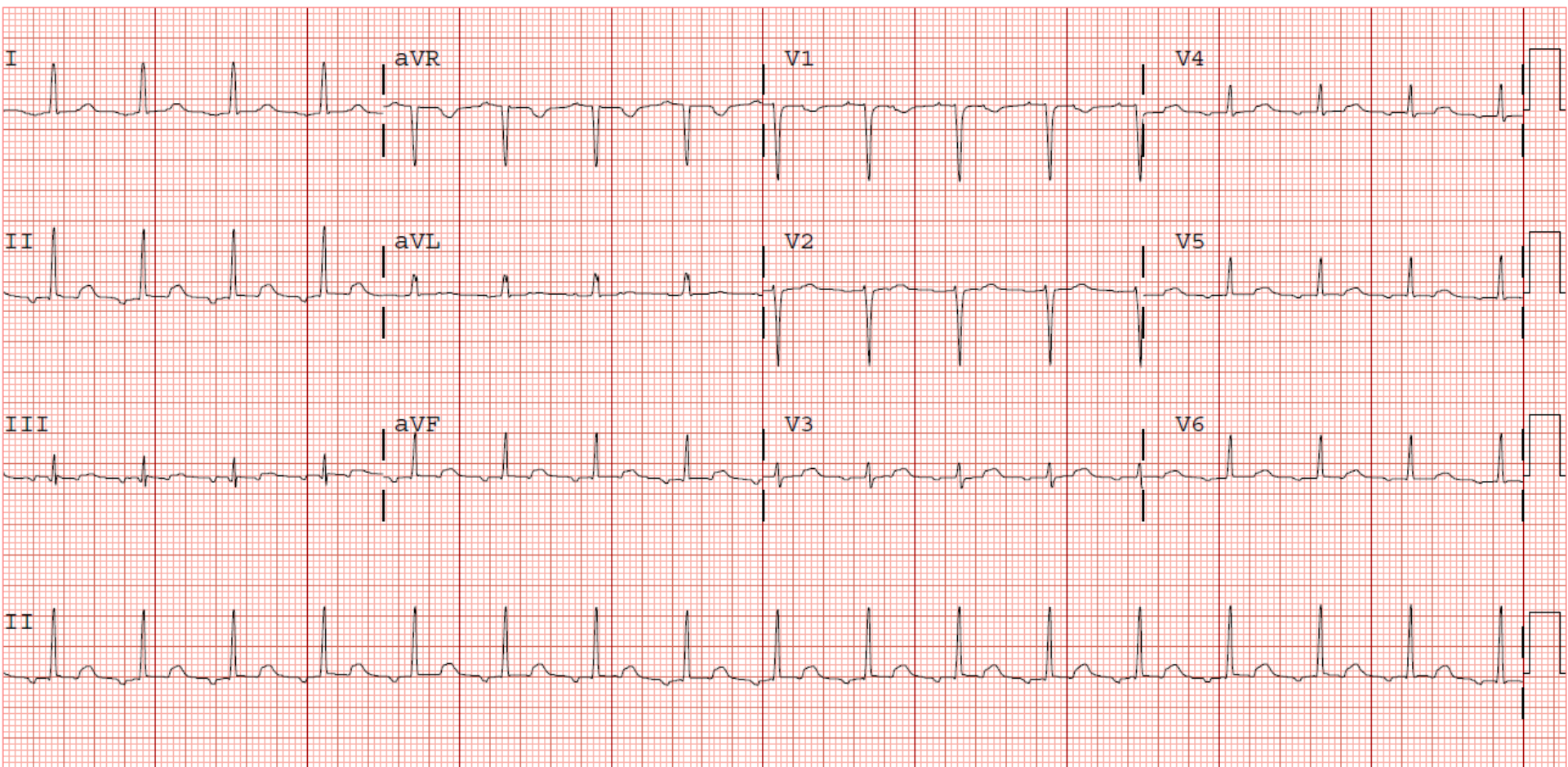
▼ Charging to 360J





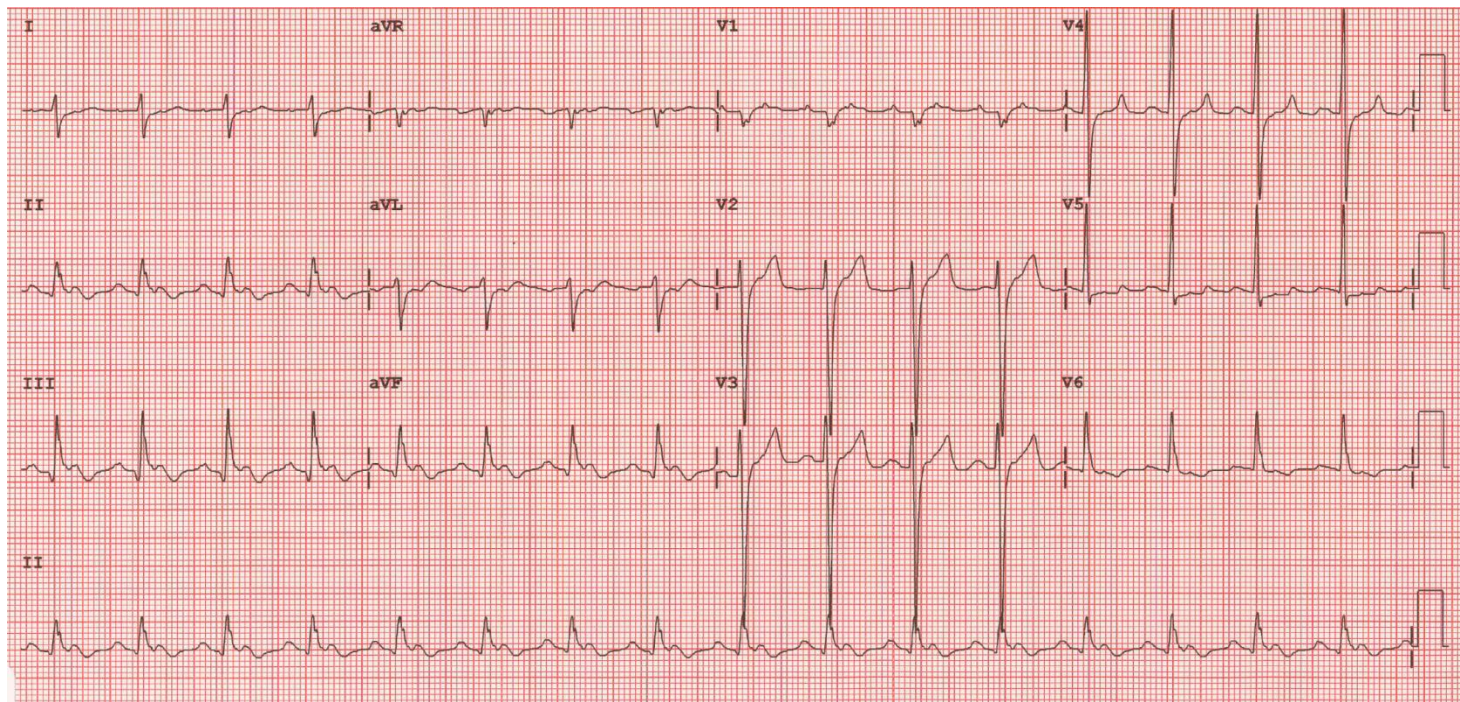
# Adenosine



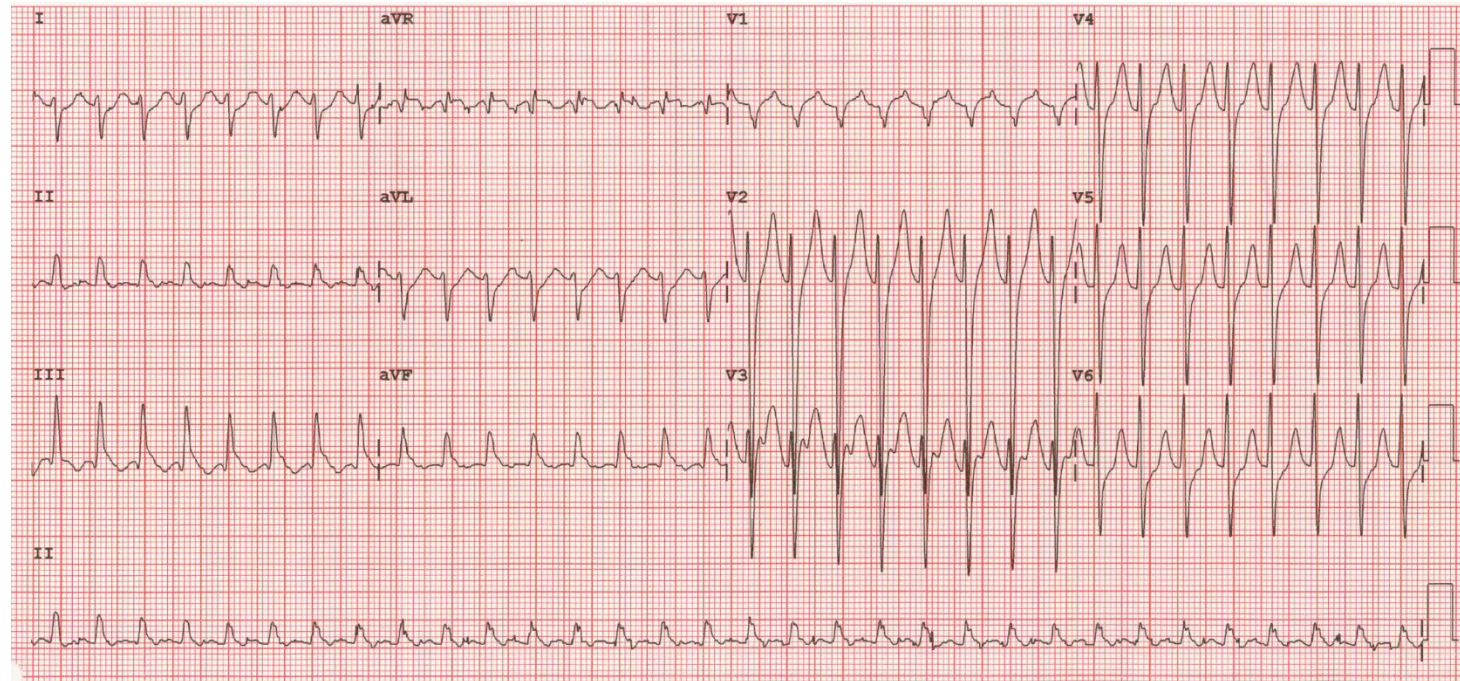




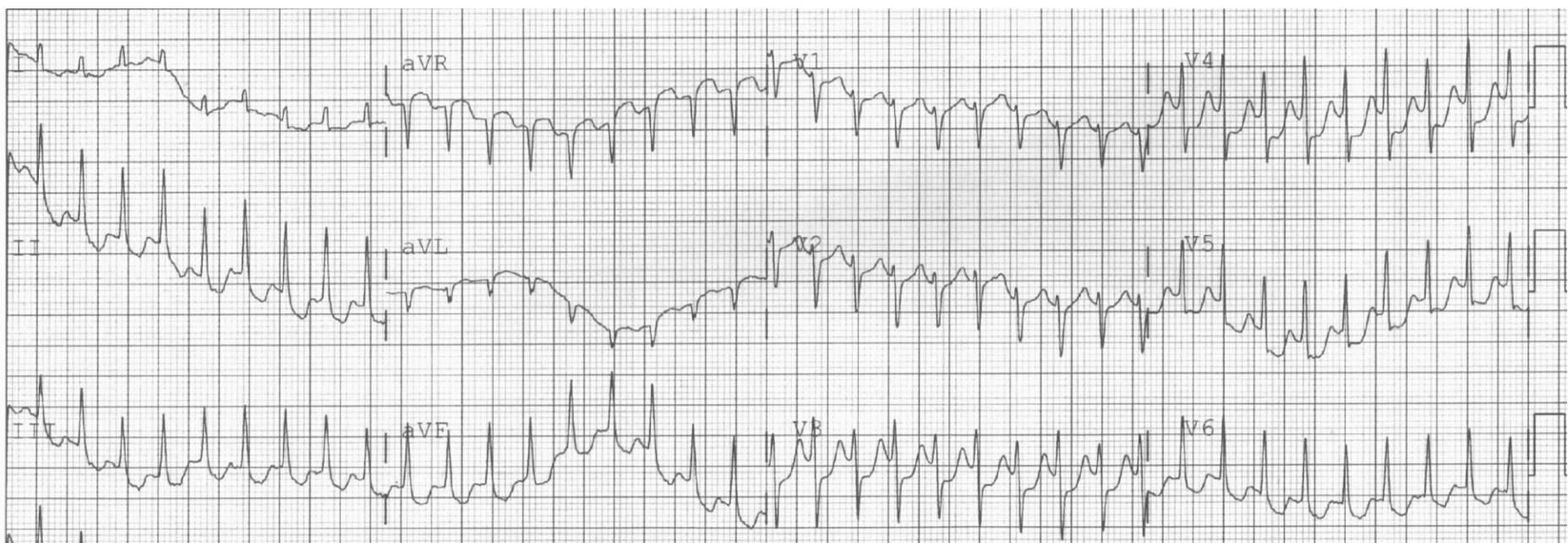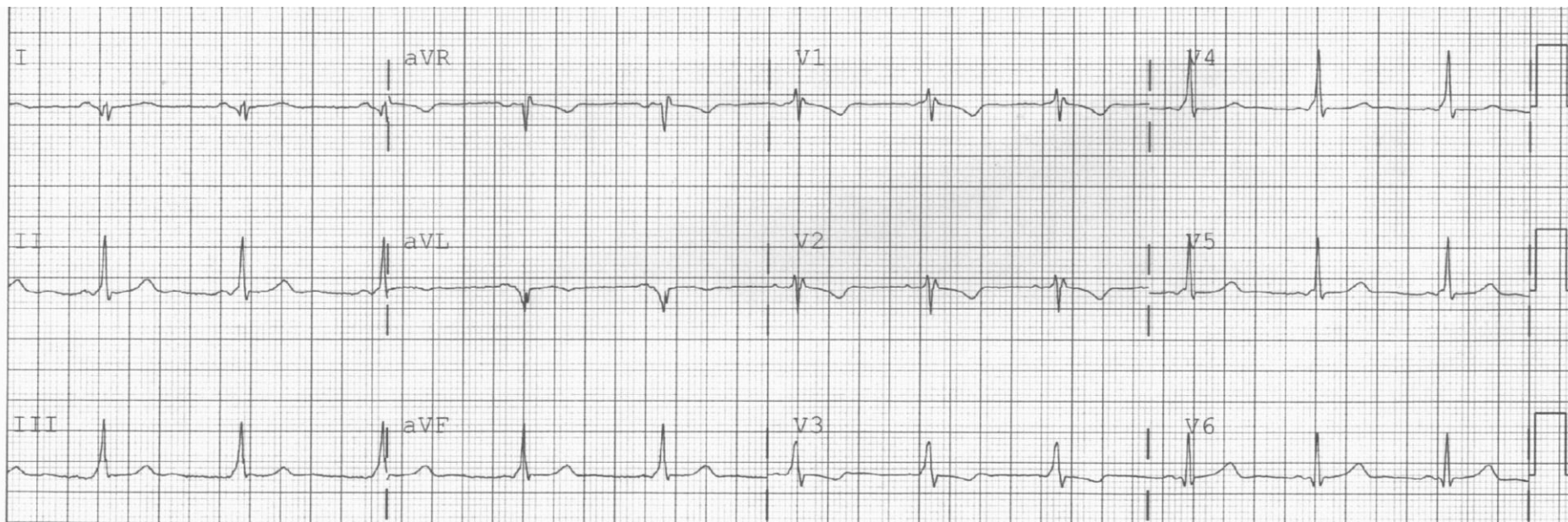
58 y.o. male with  
intermittent  
palpitations 3  
months after  
ablation for  
persistent atrial  
fibrillation; feels  
well today in clinic



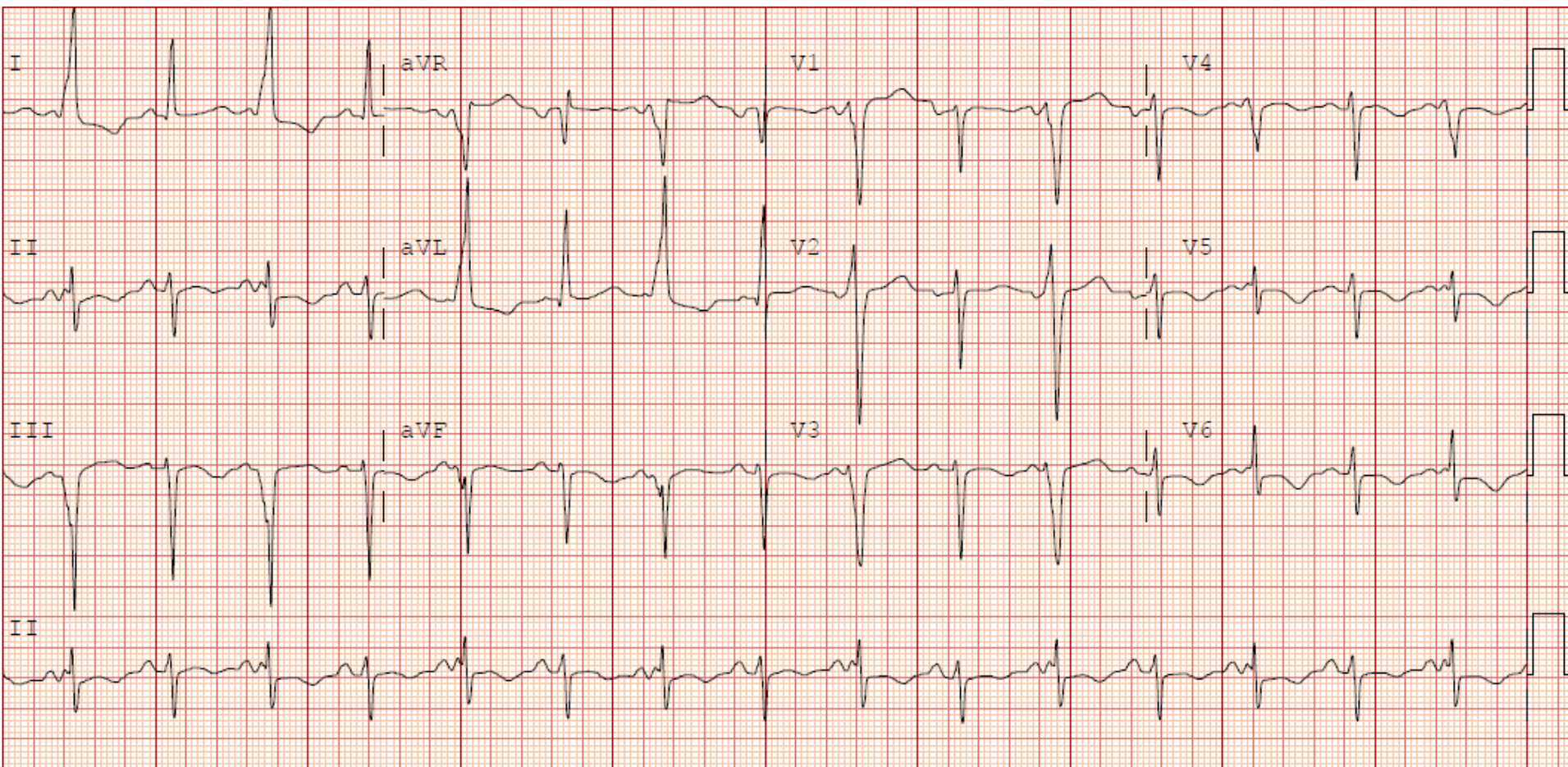
With exercise



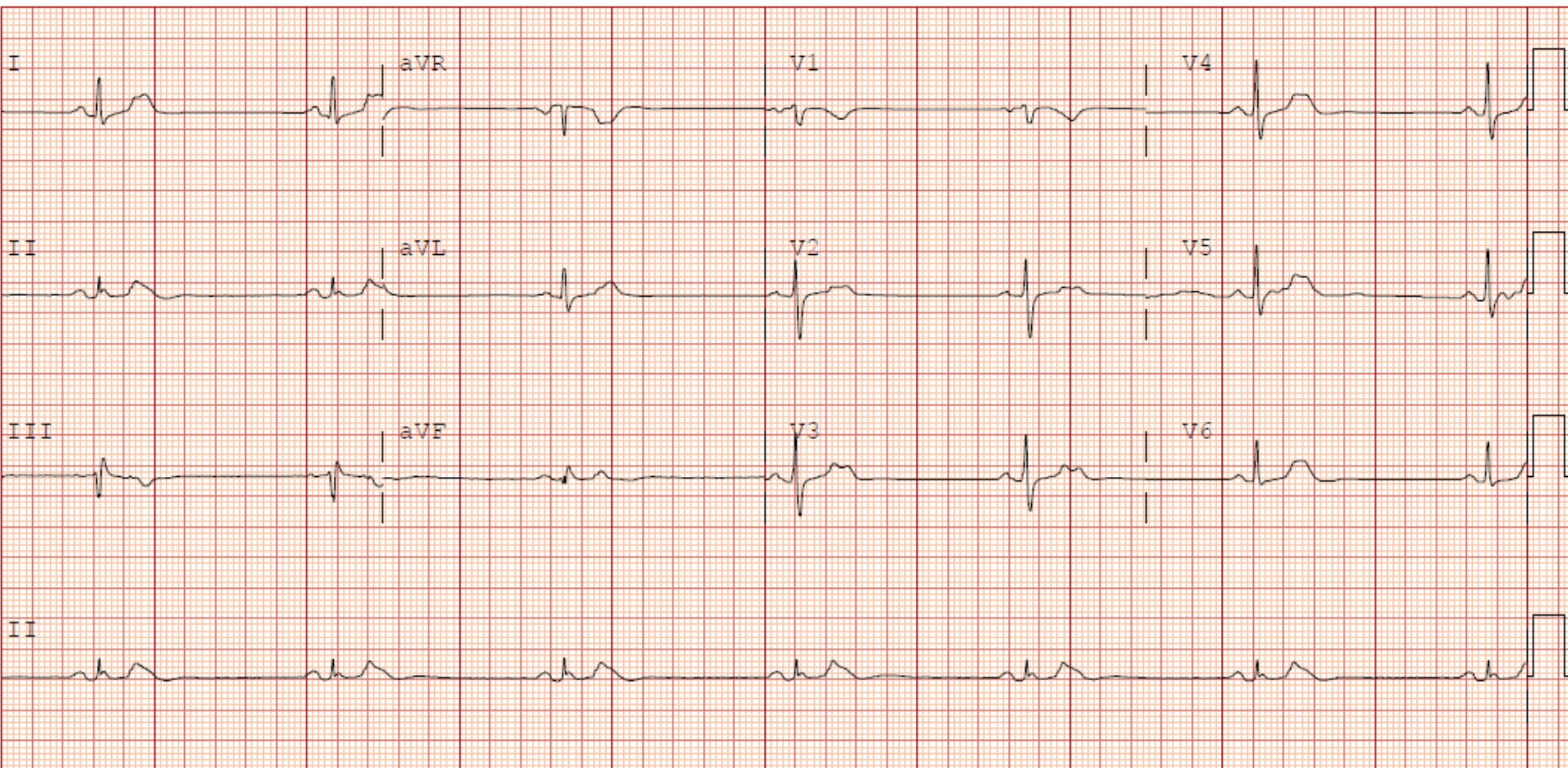




20 y.o. male with intermittent regular palpitations

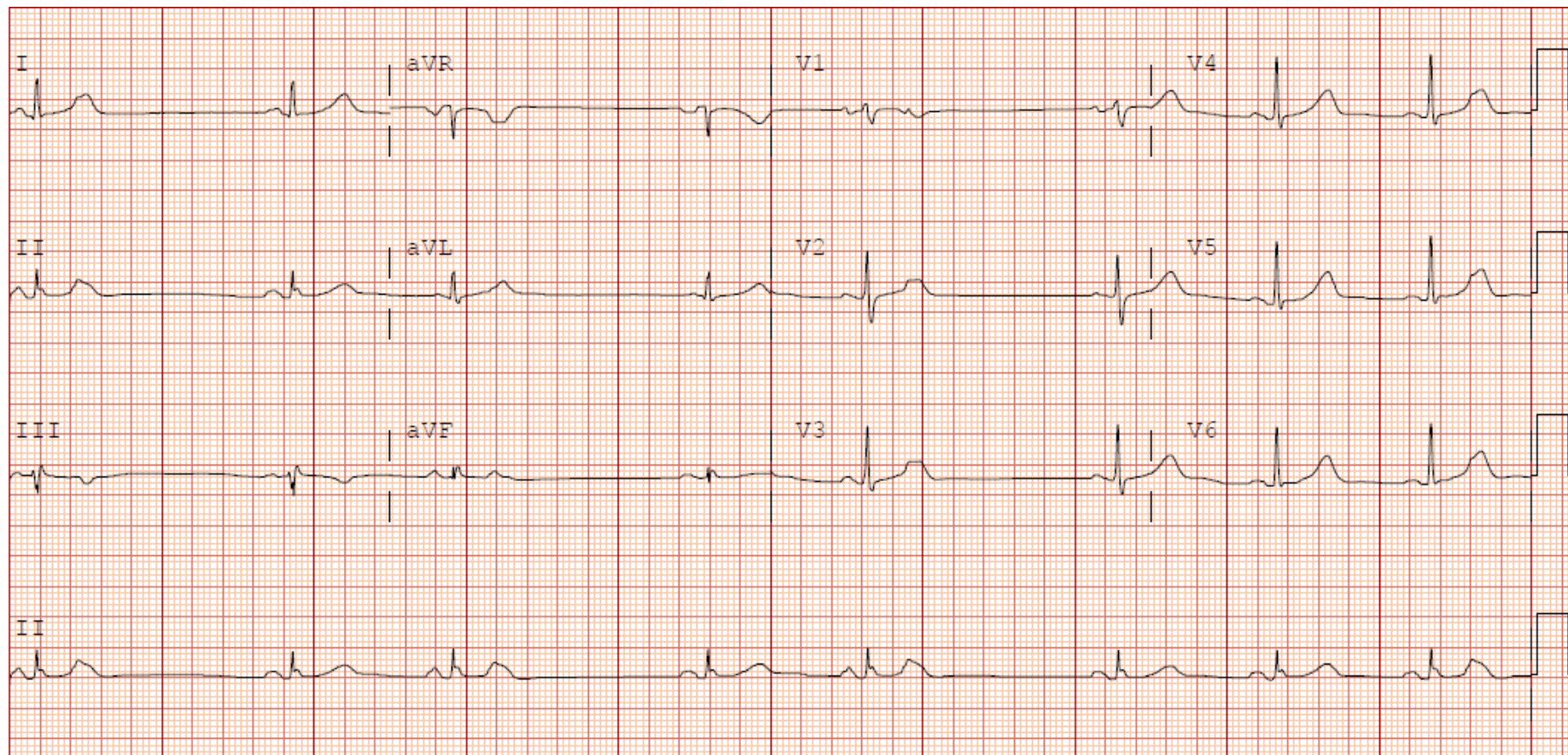


55 y.o. with paroxysmal AF, intermittent dizzy spells; initiating sotalol





55 y.o. with paroxysmal AF, intermittent dizzy spells; initiating sotalol

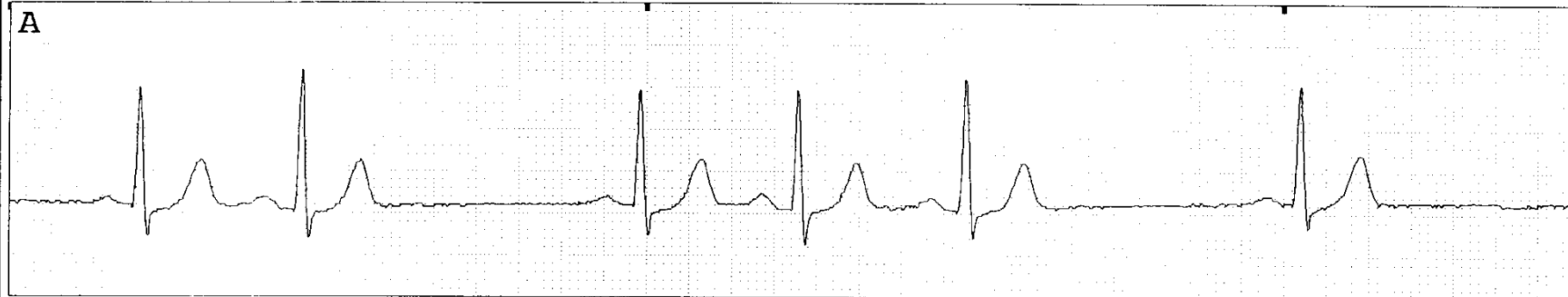




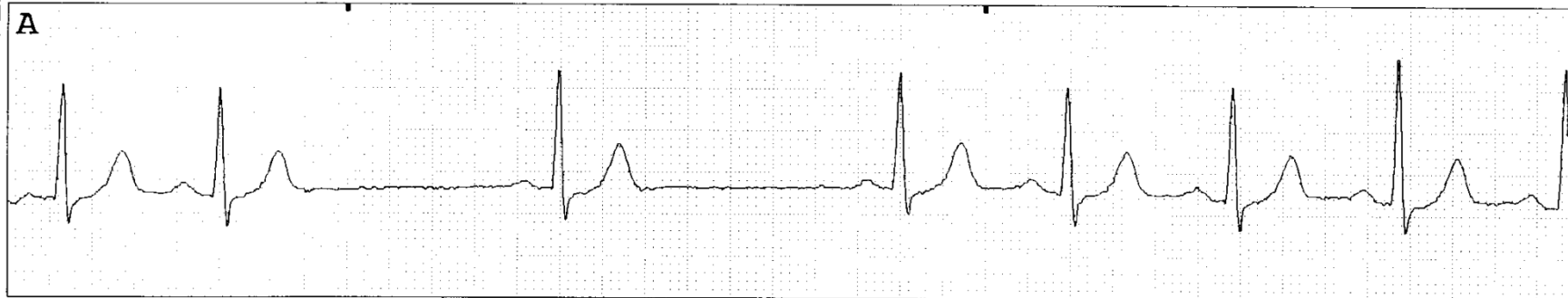
ECG 1 11:53:19 AM # Sinus Arrhythmia

HR: 47

A



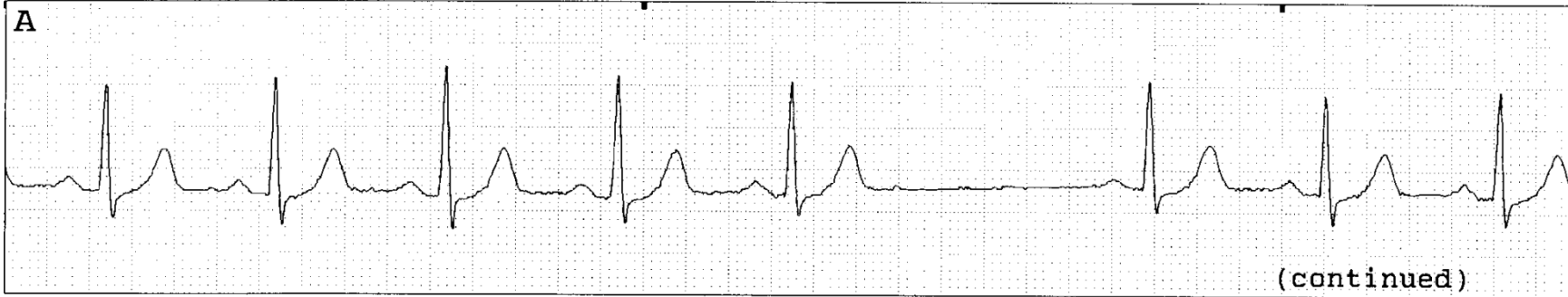
A



ECG 2 11:53:35 AM # Sinus Arrhythmia

HR: 66

A



(continued)

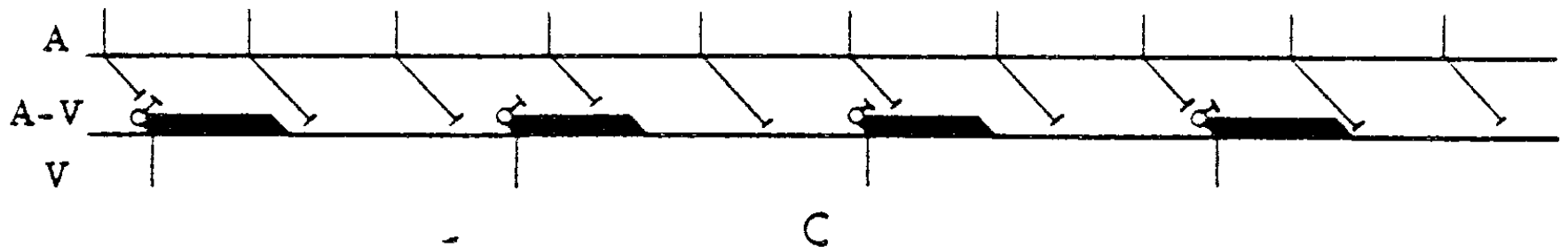
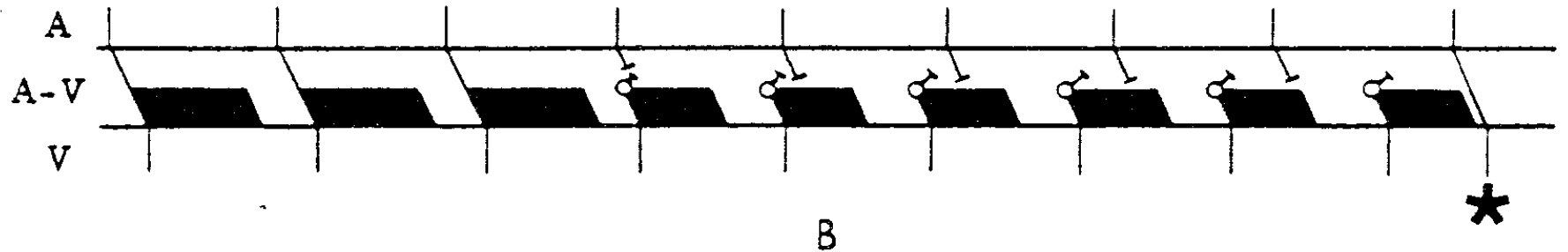
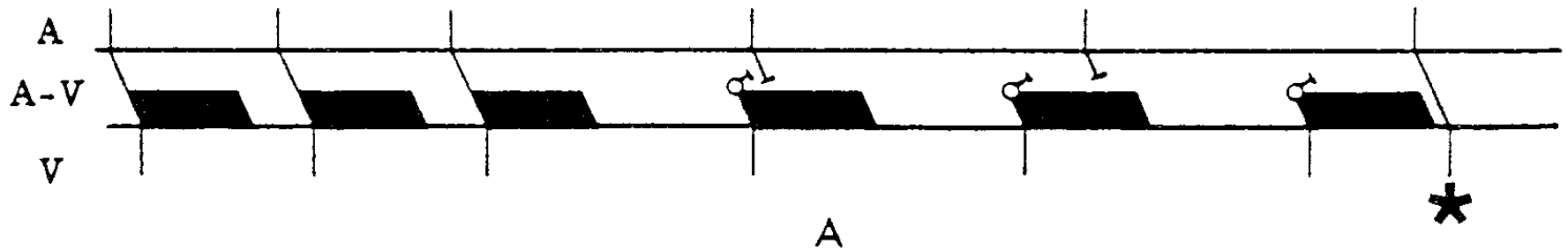
# AV Dissociation

*Not synonymous with AV block*

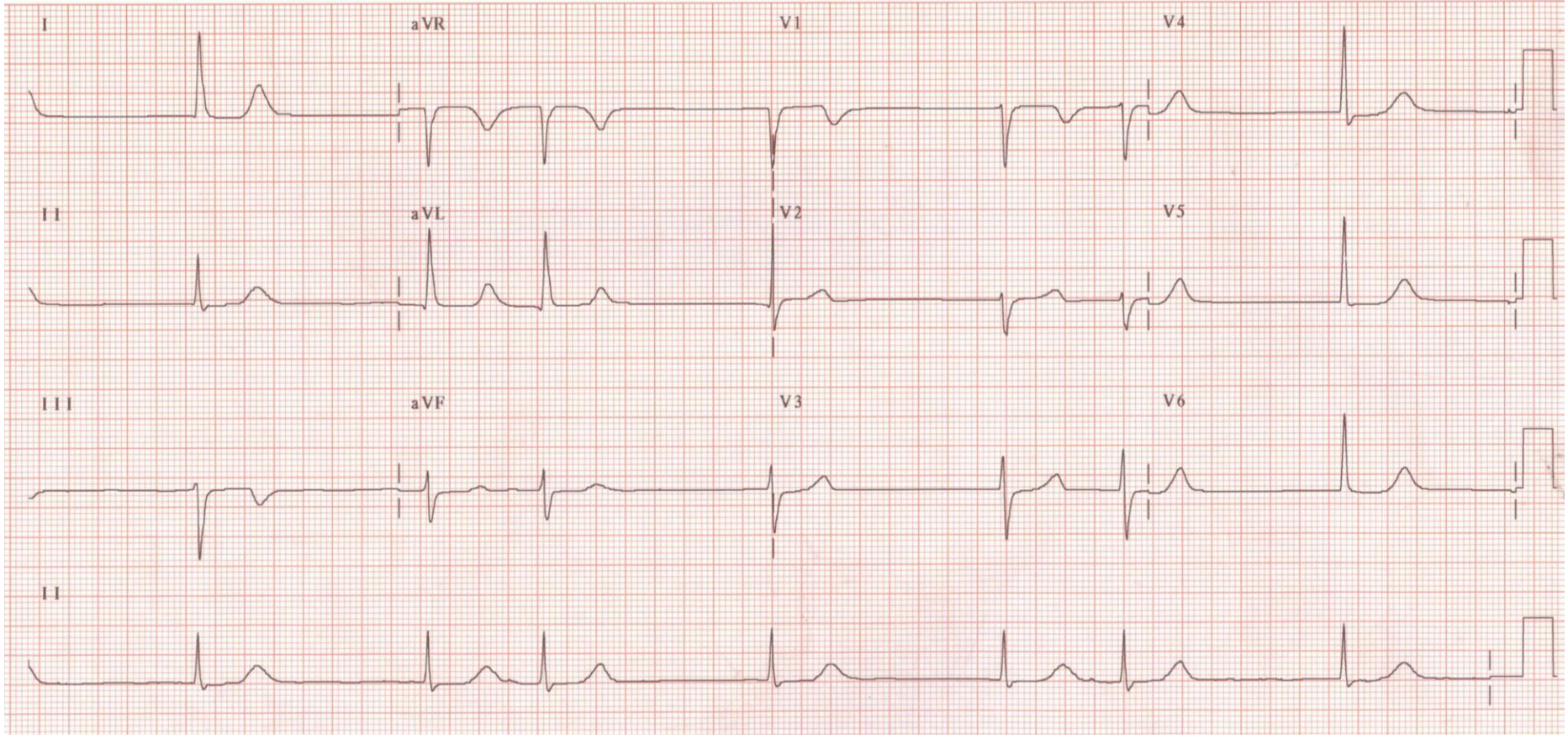
# Mechanisms of AV Dissociation

1. Slowing of primary pacemaker; subsidiary pacemaker escapes
2. Acceleration of subsidiary pacemaker; usurps control from primary pacemaker
3. Atrioventricular block (complete or incomplete)
4. Combination of 1-3

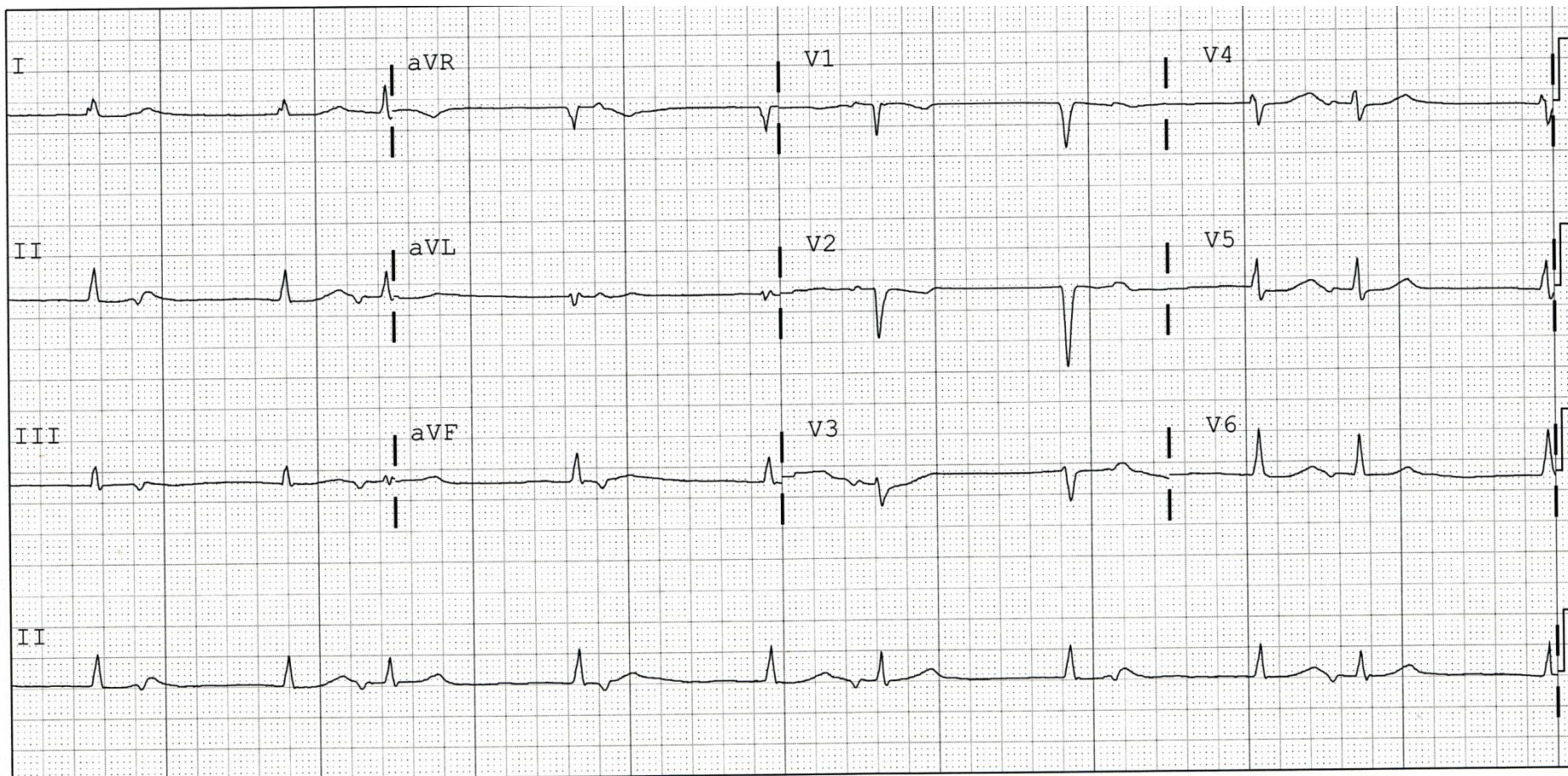
# Mechanisms of AV Dissociation

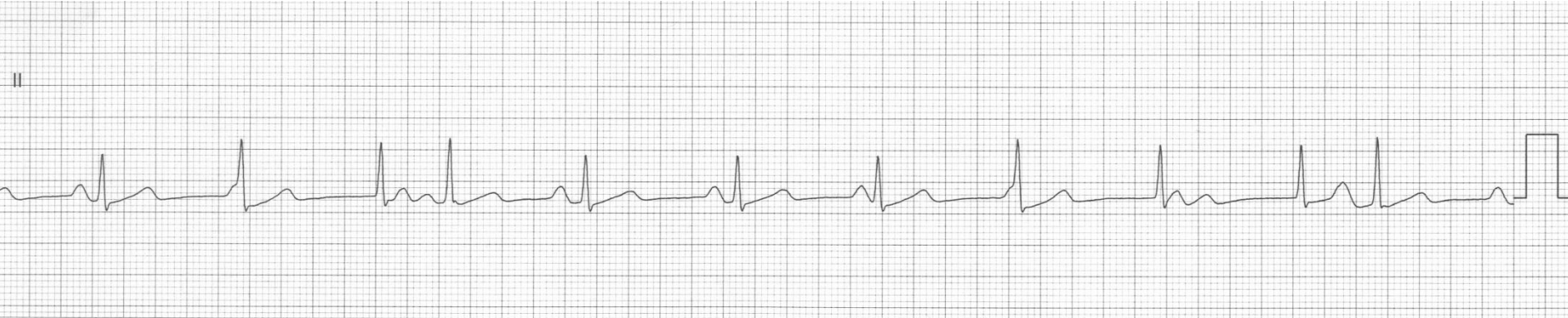






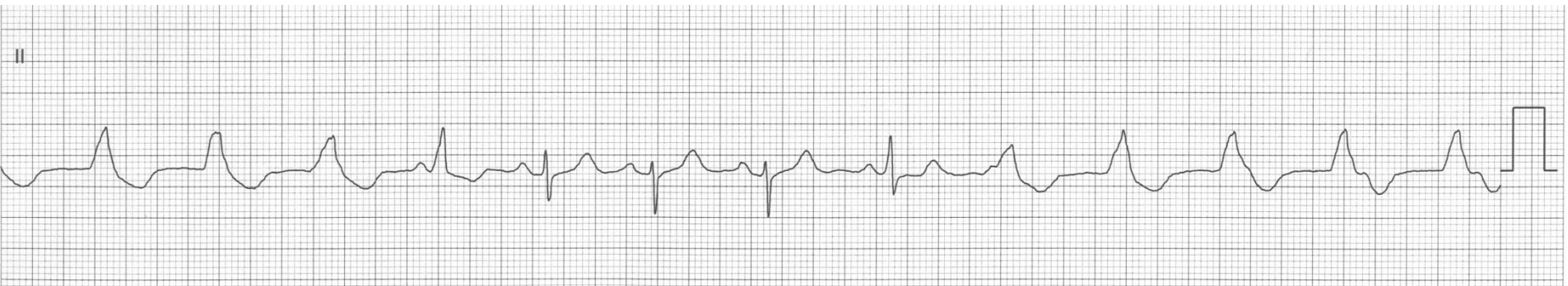
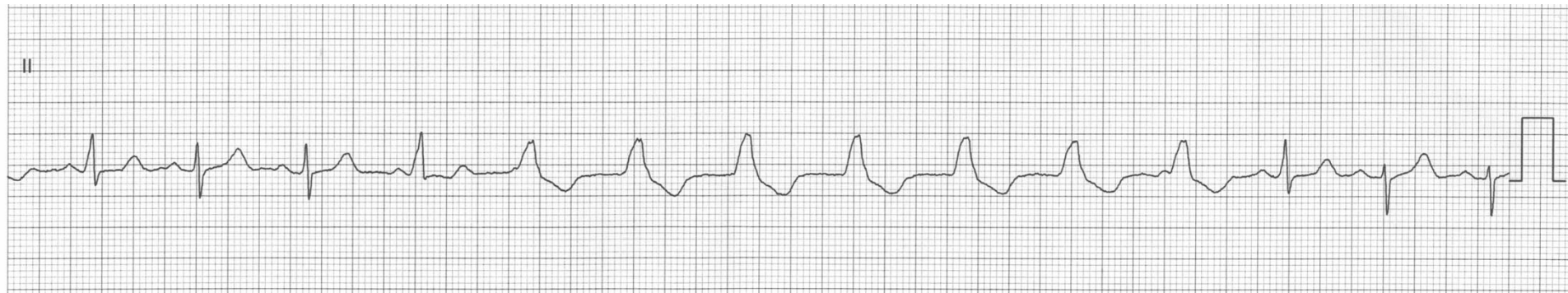




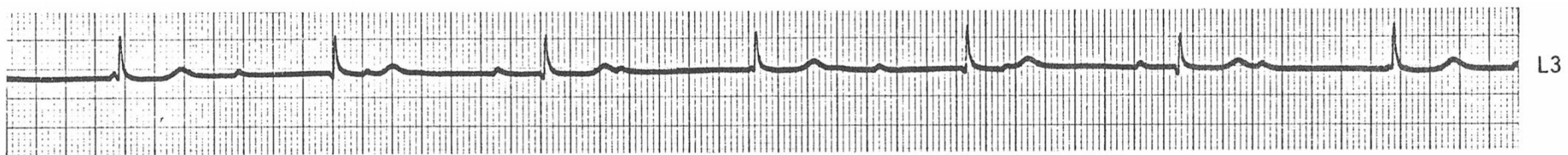


25 mm/s 10 mm/mV

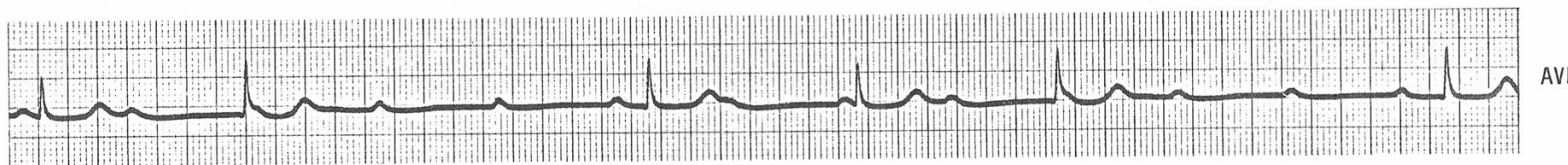
**55 y.o. male five days after CABG; asymptomatic**



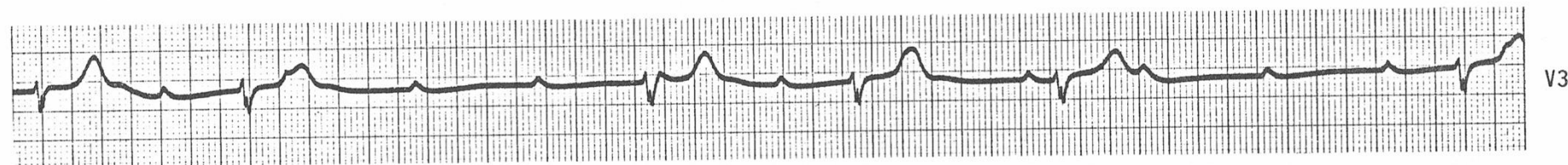




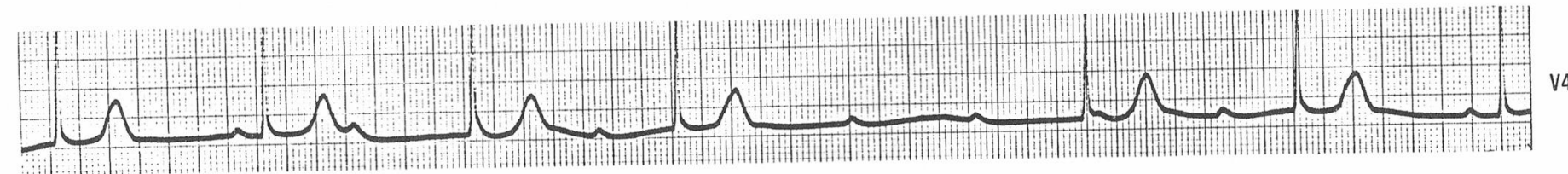
L3



AVF

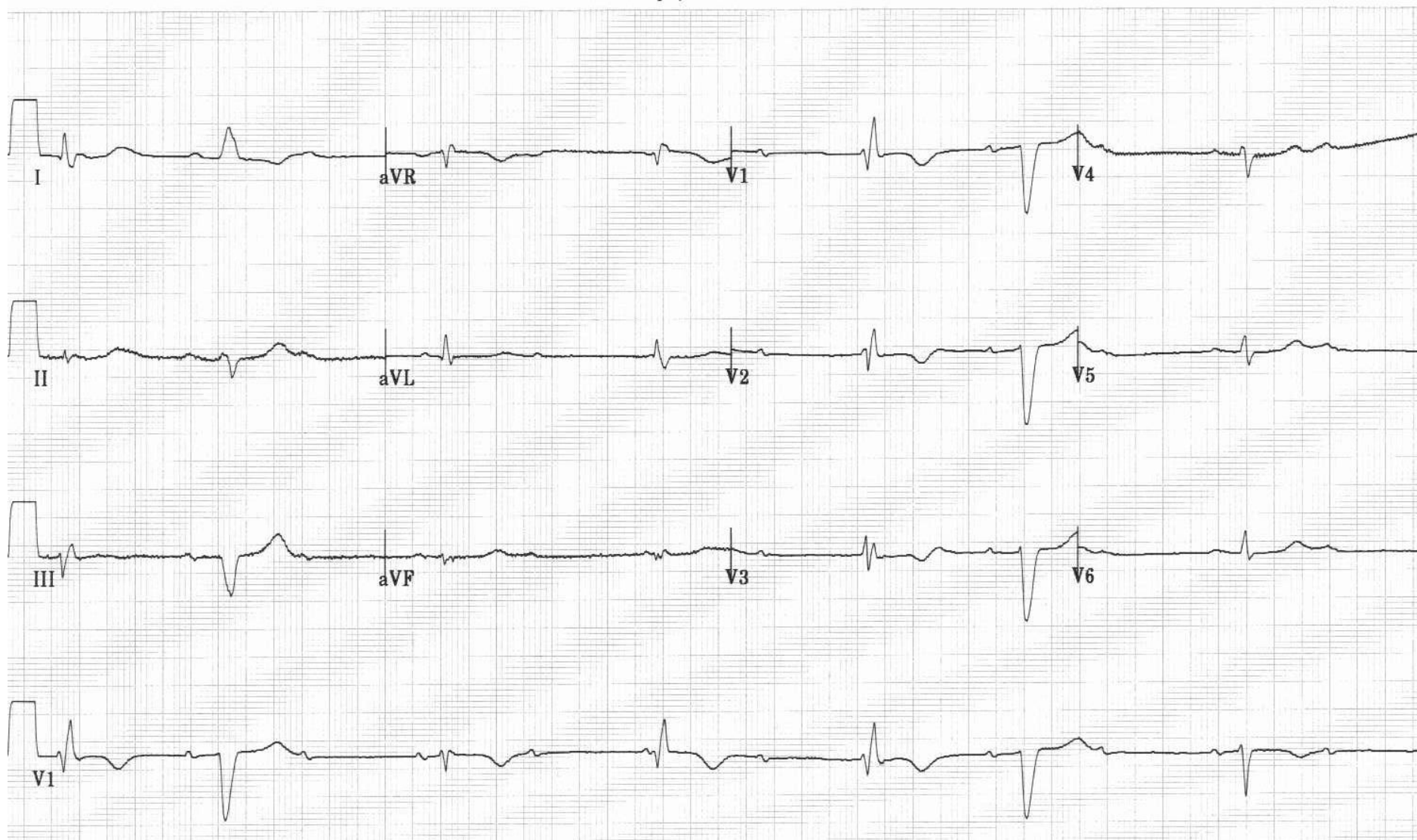


V3

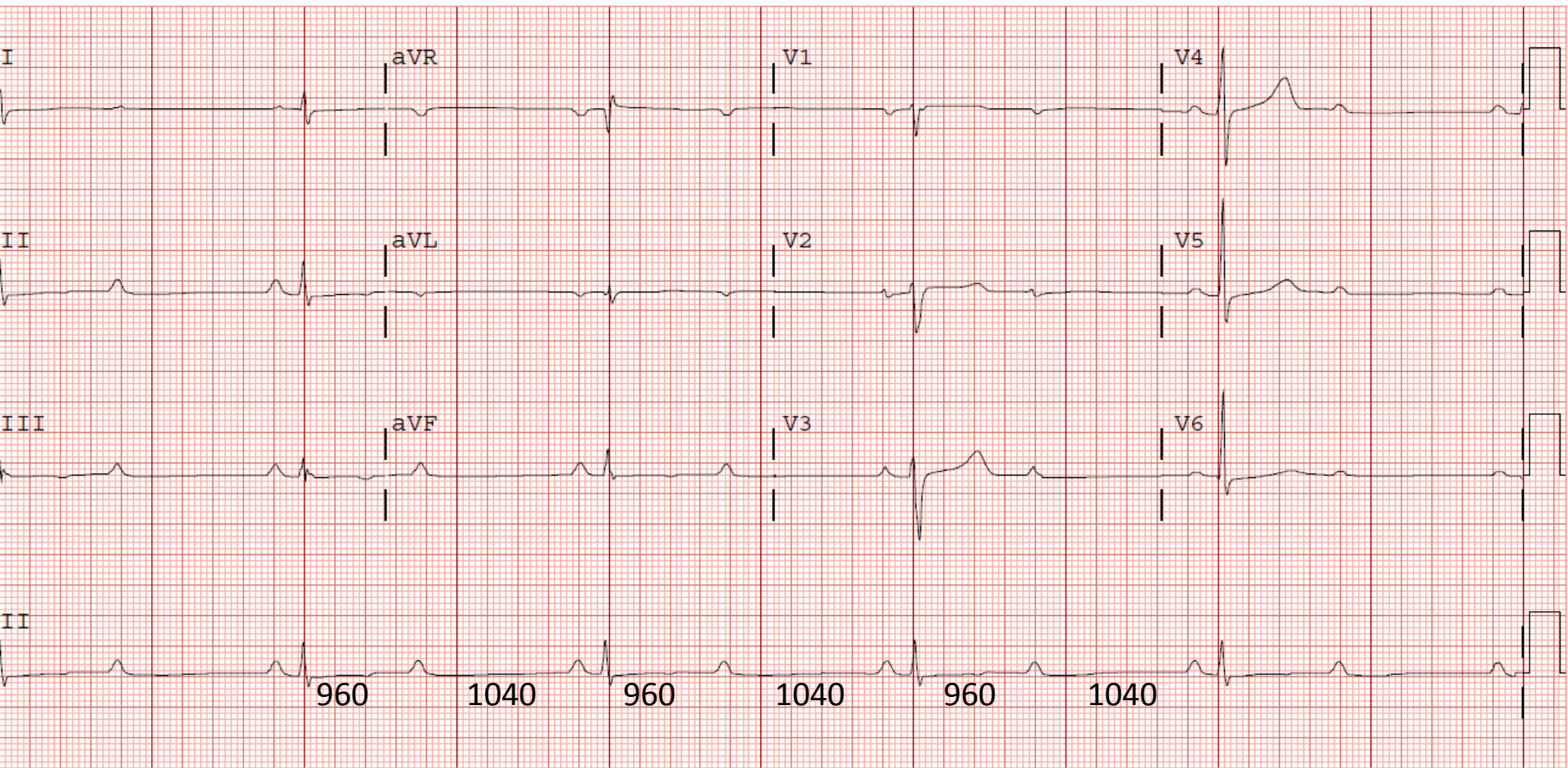


V4

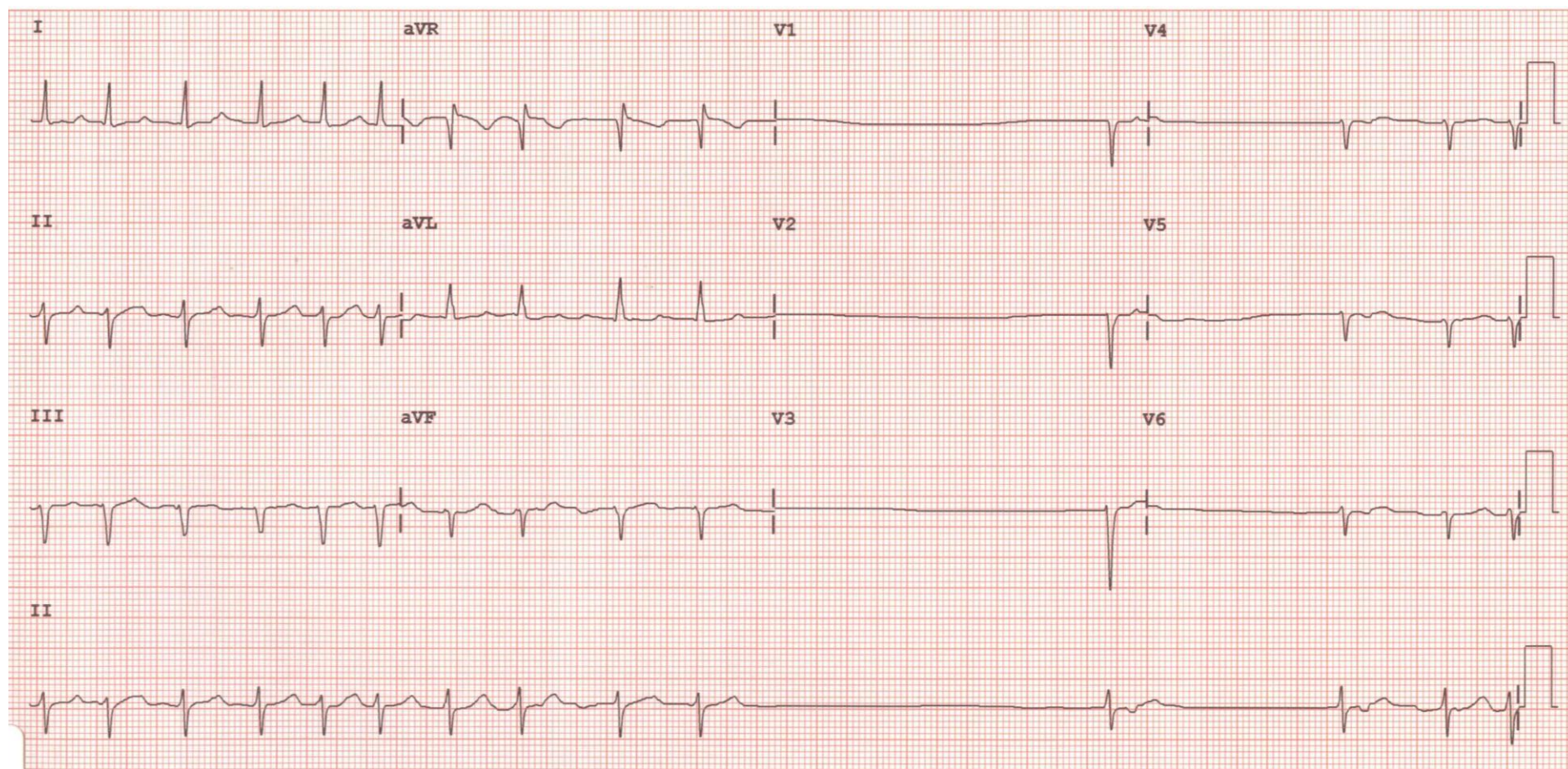




60 y.o. man, asymptomatic

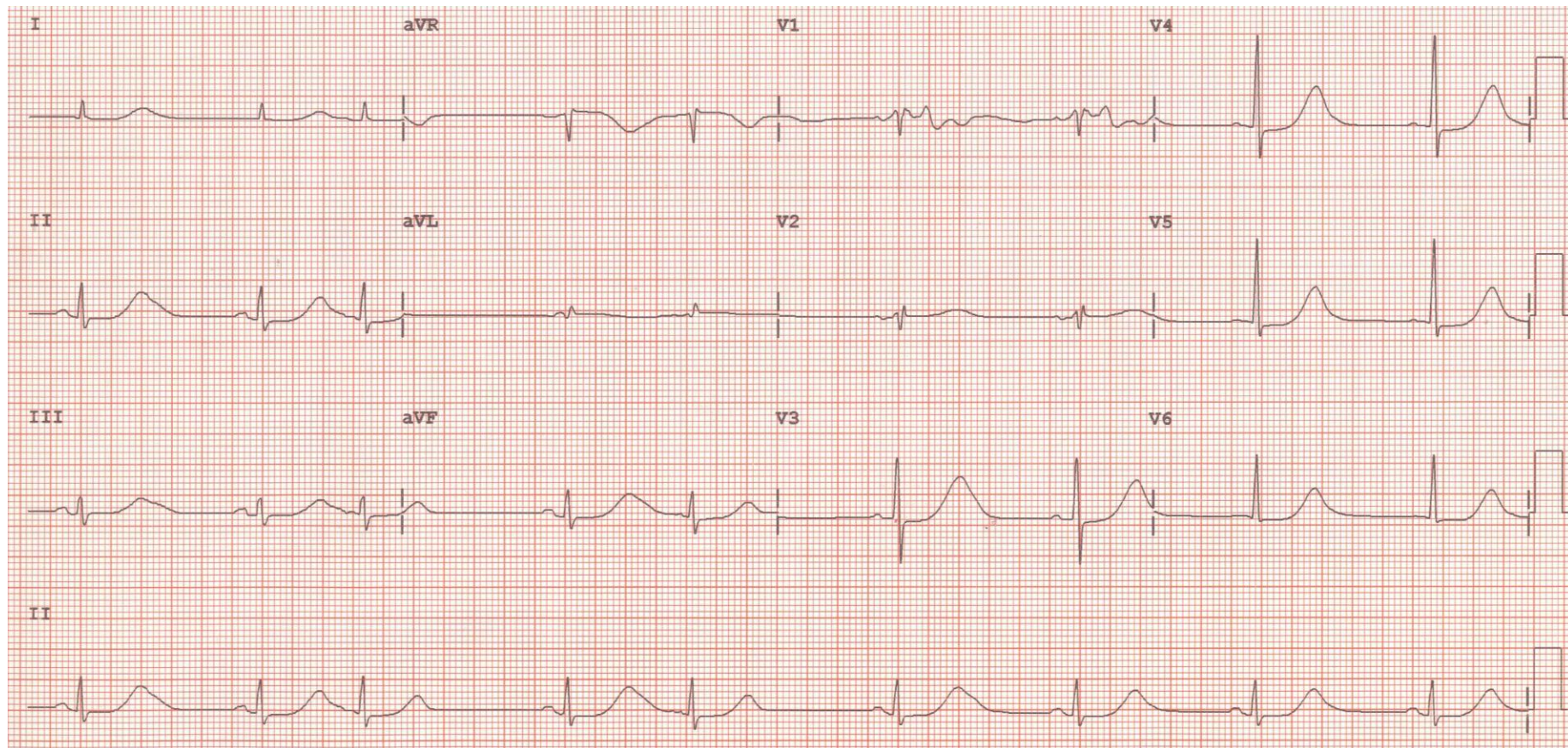




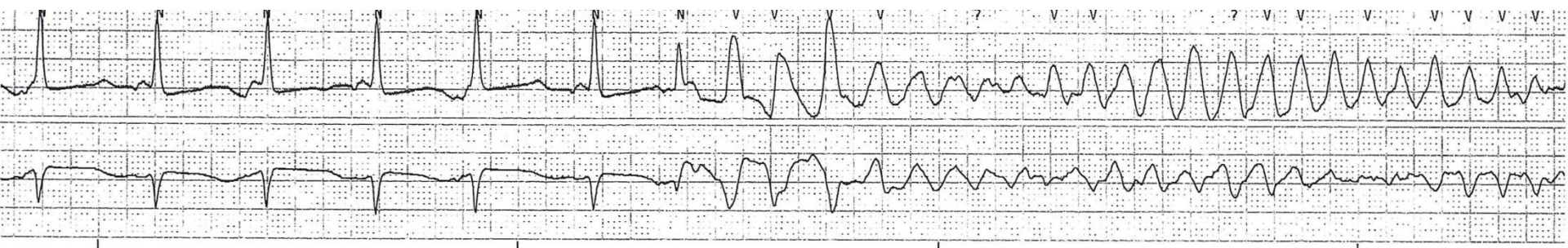
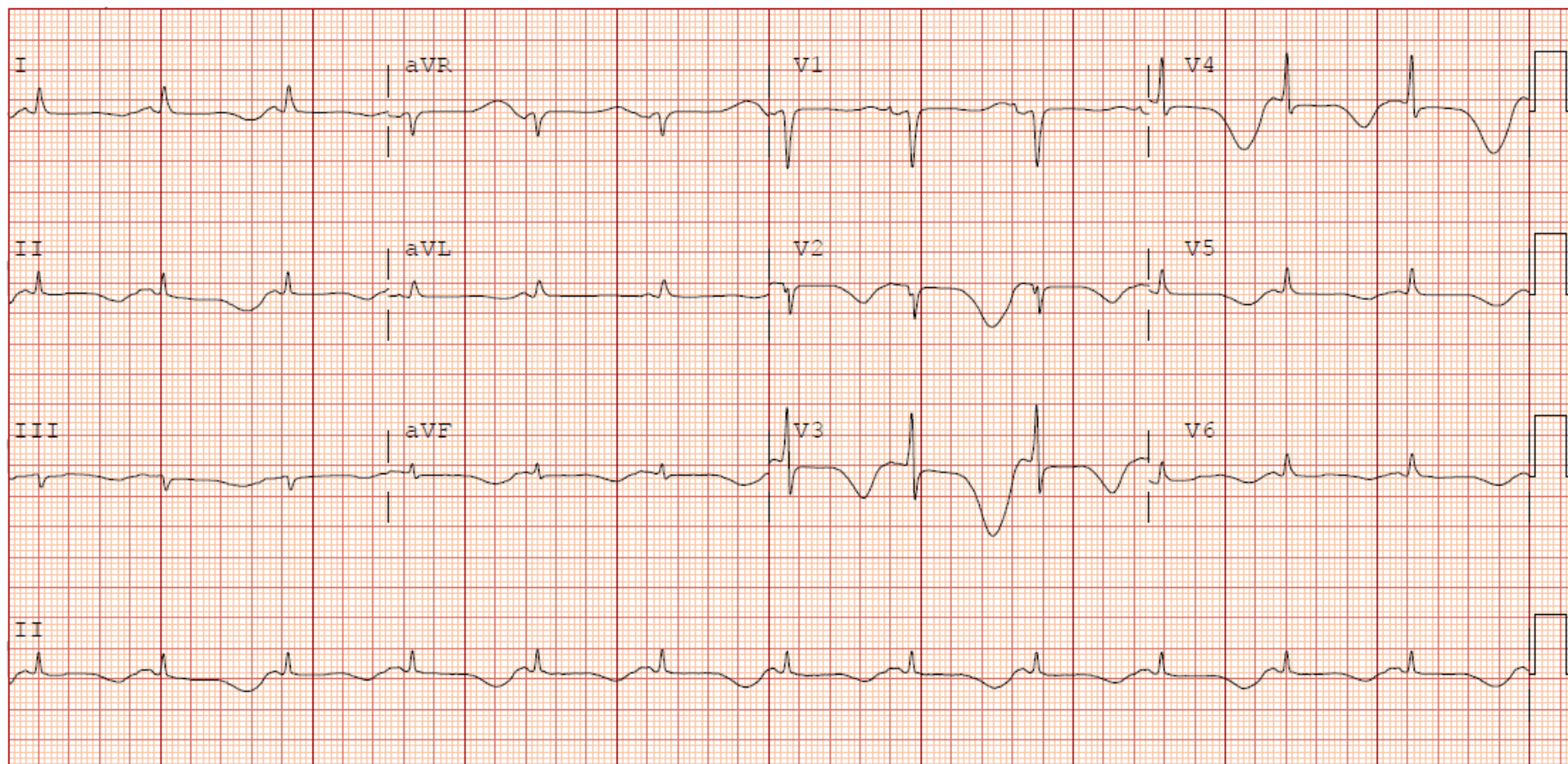




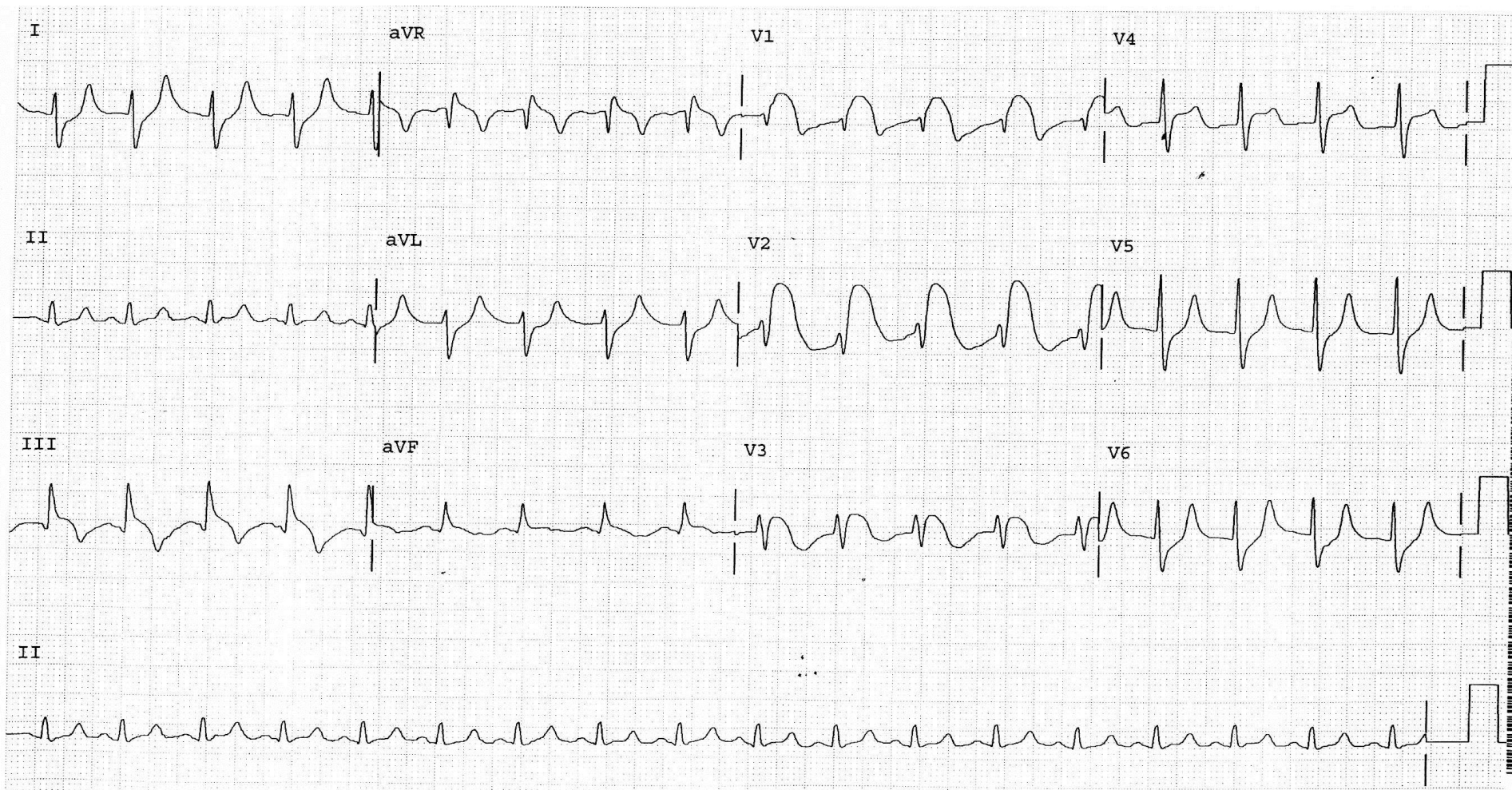
# Dofetilide



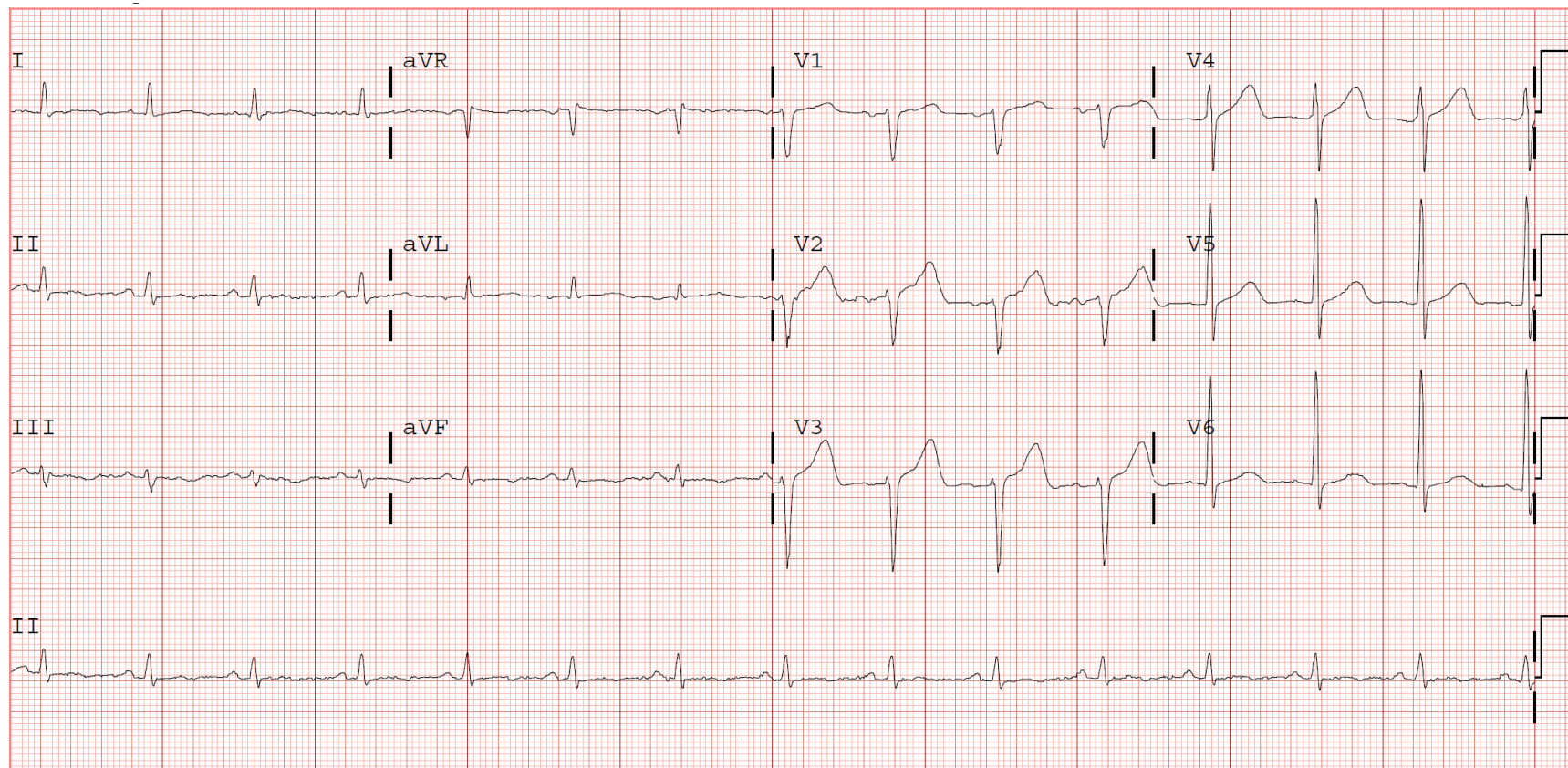




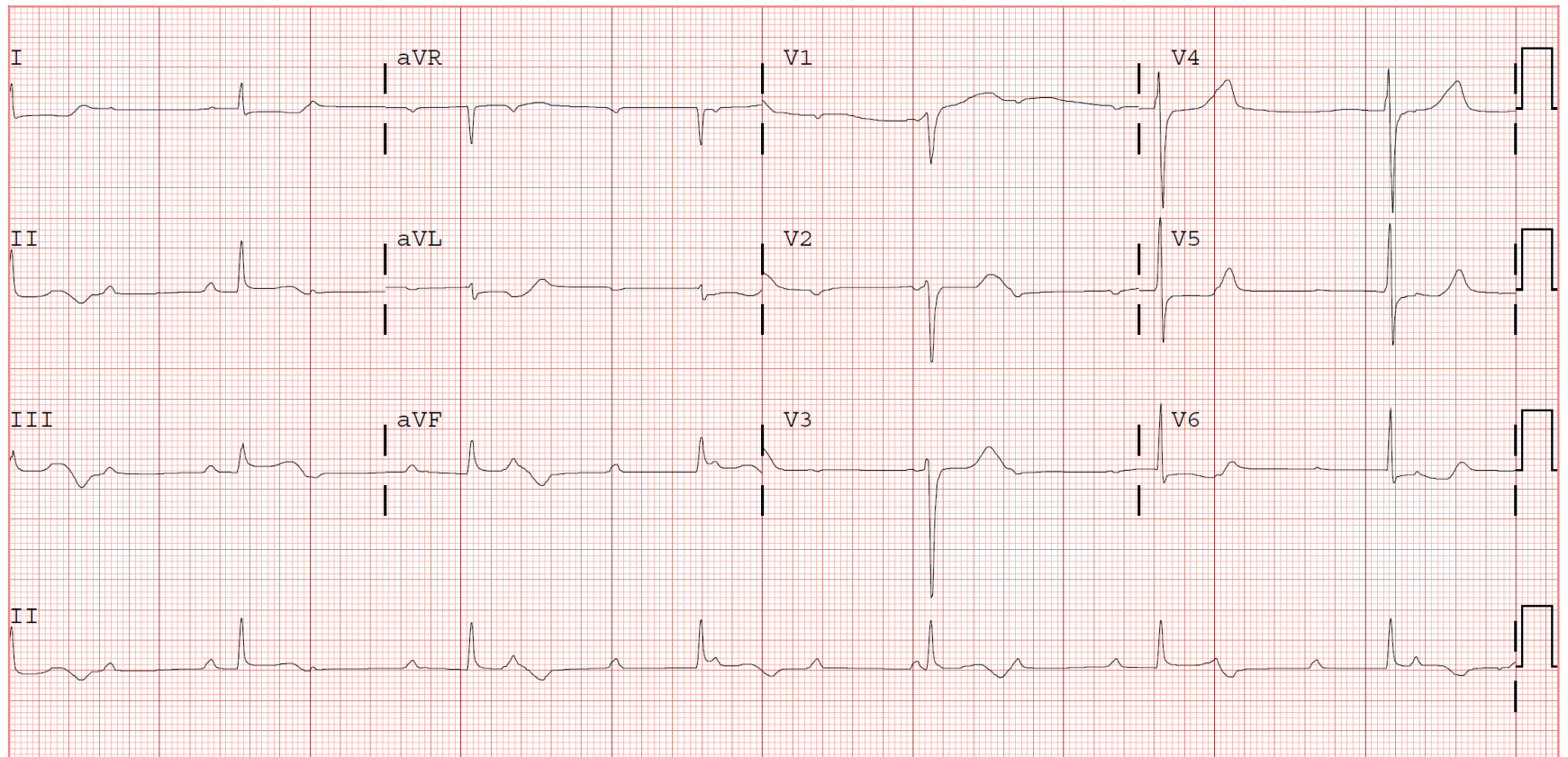
25 year old male with syncope; no chest pain.



6/17/12, 7:58

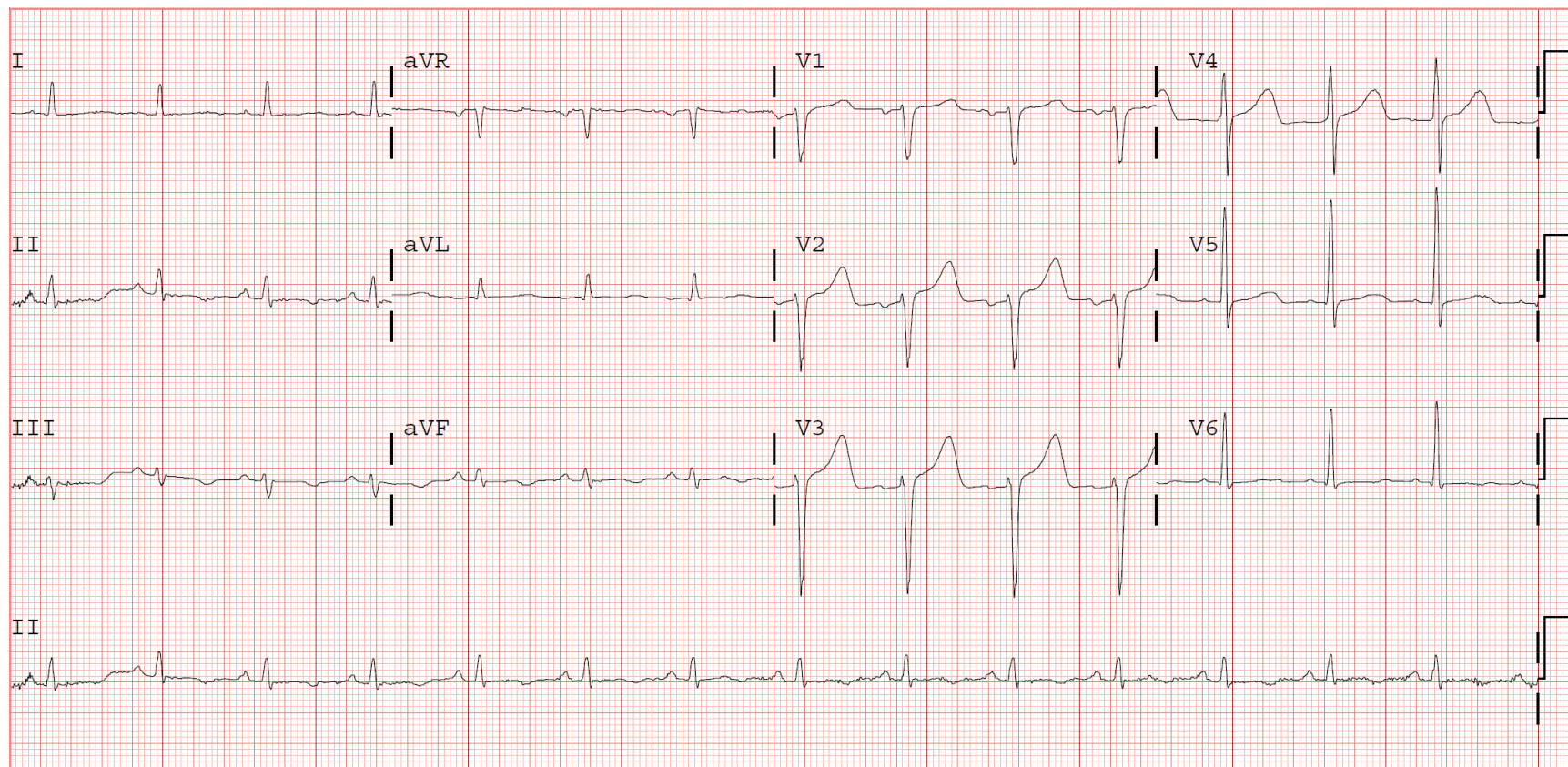


6/17/12, 14:09





6/17/12, 14:19



## 44 y.o. heart transplant patient doing well

